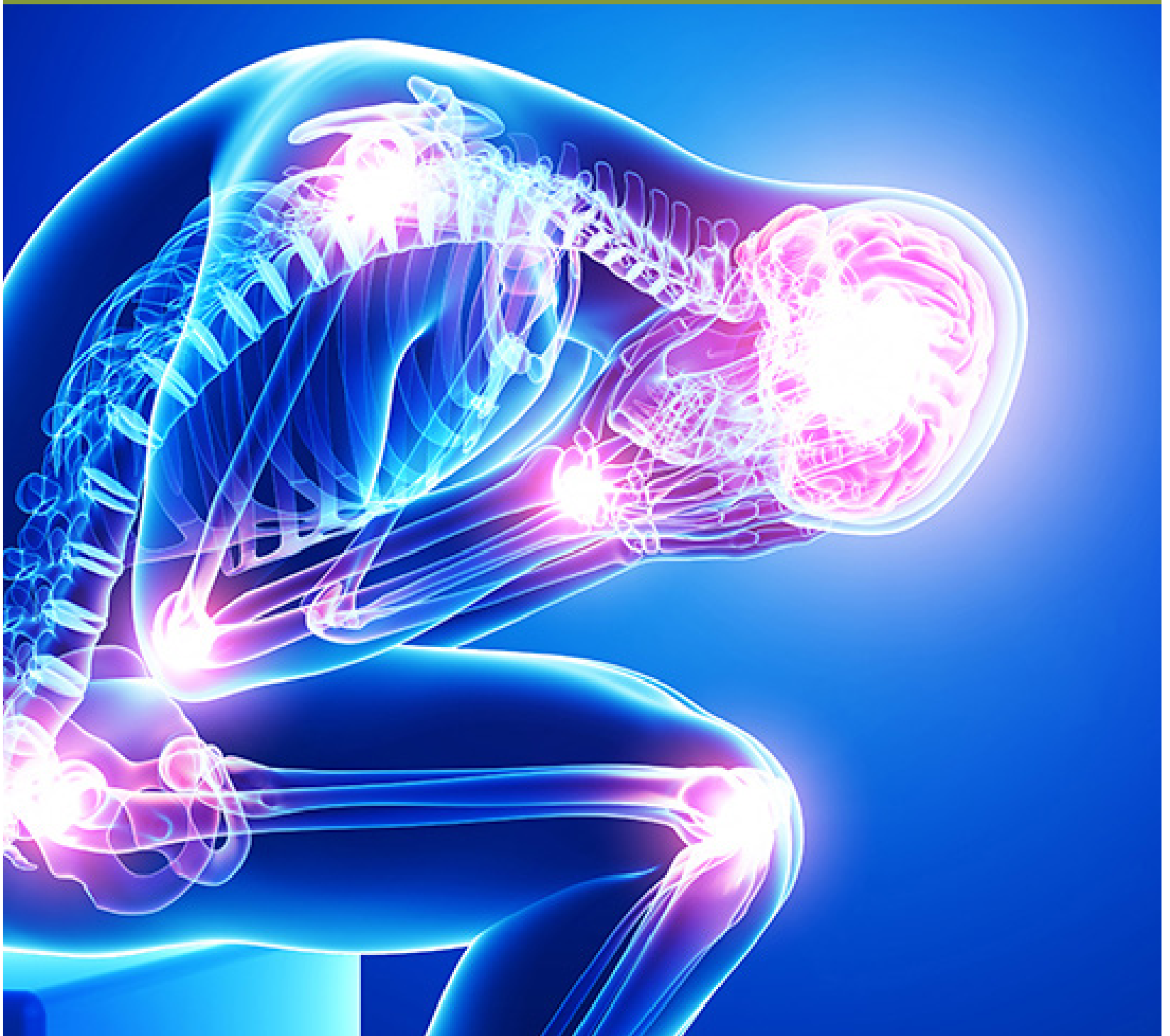
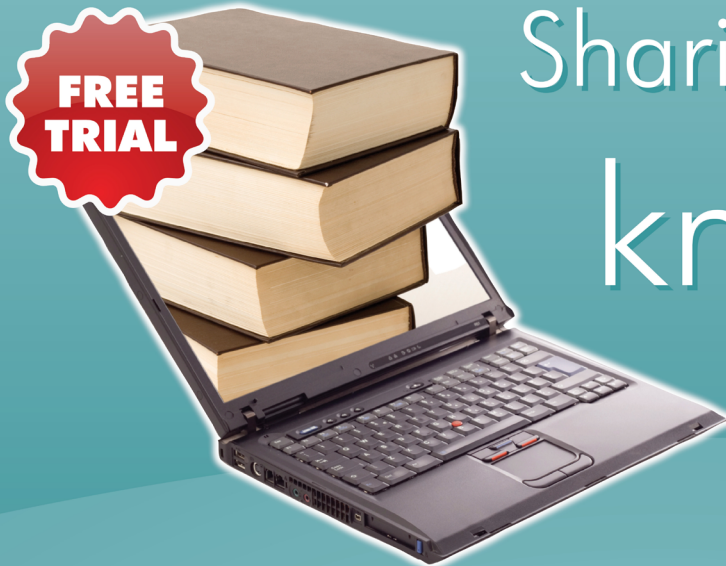
# FOUNDATION YEARS JOURNAL

MAY 2018

Volume 12, Issue 5: Orthopaedics & Radiology

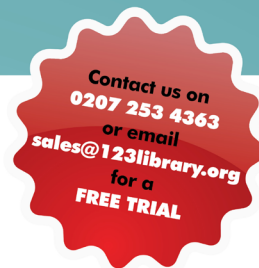



## Sharing **more** knowledge



## What is 123Library?



123Library is a fast growing and innovative eBook and **digital content provider for libraries** in the field of healthcare.

## What are the benefits for your library?

- 1 FULL FLEXIBILITY ✓
- 2 KNOWLEDGE ✓
- 3 CUSTOMER CARE ✓
- 4 NO HASSLES ✓
- 5 FULL SECURITY ✓
- 6 GET FEEDBACK ✓
- 7 SUPPORT ✓
- 8 EASE OF USE ✓
- 9 SAVING MONEY ✓

Benefit today, visit [www.123Library.org](http://www.123Library.org)

# 123Library

## 4-5 EDITORIAL BOARD

Orthopaedics & Radiology

## 6-42 ORTHOPAEDICS

## 6-11 GOOD CLINICAL CARE

Obtaining Joint Fluid In An  
Emergency Setting: A Guide For  
Aspirating Native Joints

*G Crate, L Maling, J Relwani*

## 12-15 GOOD CLINICAL CARE

Managing A Plastic  
Surgery On-Call

*C Brady*

## 16-21 CASE BASED DISCUSSION

Understanding The Importance  
Of The Neurovascular Status  
Assessment In The Care Of Patients  
With Proximal Tibia Fractures

*O Hodge, D Woods*

## 22-24 CASE BASED DISCUSSION

The Management Of Bursitis

*KS Khor, P Achan*

## 25-29 CASE BASED DISCUSSION

Orthopaedics: Acute  
Compartment Syndrome

*N Pakroo, F Wong, J Walczak*

## 30-36 CASE BASED DISCUSSION

Early Management Of Major  
Trauma In The Older  
Adult Patient

*C Richardson, R Wharton, M Pearce*

## 37-42 CASE BASED DISCUSSION

Hip Joint Pain In Young,  
Active Patients

*PG Robinson, P Gaston*

## 43-75 RADIOLOGY

## 43-46 CASE BASED DISCUSSION

A Patient Presents With  
Acute Abdominal Pain

*A Oakes, C Patel, R Chakravartty, S Idriz*

## 47-56 TEACHING & TRAINING

Radiology: A Sneak Peek Into The  
Dark Side To The Outside World

*S Ramachandriah, C Peebles*

## 57-60 PATIENT MANAGEMENT

Imaging A Patient With  
Acute Breathlessness

*R Chakravartty, A Oakes,  
A Antonello, C Patel, V Prakash*

## 61-64 CASE BASED DISCUSSION

Article Pleural Drains  
Track Changes

*C Patel, S Idriz, A Oakes, R Chakravartty*

## 65-69 CASE BASED DISCUSSION

Sinistral Portal Hypertension:  
A Poorly Recognised Entity

*S Zafar, YJ Lee, F Kazmi, N Khan*

## 70-75 TEACHING & TRAINING

Foundation Doctors'  
Knowledge Of Radiation  
Legislation & Exposure

*M Adil, S Tanzeem, H Raza, M Vassallo*

## FOUNDATION YEARS JOURNAL 2018

Volume 12

## Foundation years journal

Foundation Years Journal is an international peer-viewed journal which seeks to be the pre-eminent journal in the field of patient safety and clinical practice for Foundation Years' doctors and educators. The Journal welcomes papers on any aspect of health care and medical education which will be of benefit to doctors in the Foundation training grade in the UK or international equivalents.

## Editor in chief

**Dr Hasan Tahir BSc, MB, BS, D Sports Ex-Med, MSc, MFSEM (UK), FRCP (UK)**

Consultant Physician in Rheumatology & Acute Medicine  
*Barts Health NHS Trust, London*

Honorary Reader in Clinical Investigational Rheumatology  
*William Harvey Research Institute  
Barts and the London School of Medicine and Dentistry*

Professor of Clinical Medicine  
*St Matthews University Hospital School of Medicine*

## Publisher's office

**Sophie Wood (Managing Editors)**

123 Library, 72 Harley Street, London, W1G 7HG  
Tel: +44 (0)207 253 4363 | Email: [sophiewood@123doc.com](mailto:sophiewood@123doc.com)

## Editorial board

**Mr Paul Gaston**

Consultant Orthopaedic Surgeon  
Royal Infirmary of Edinburgh  
51 Little France Crescent, EH16 4SA  
[paul.gaston@ed.ac.uk](mailto:paul.gaston@ed.ac.uk)

**Mr David Woods**

Orthopaedic Consultant  
Great Western Hospital  
Marlborough Road  
Swindon, SN3 6BB  
[david.woods7@nhs.net](mailto:david.woods7@nhs.net)

**P Achan**

Department of Trauma and Orthopaedics  
Royal London Hospital, Whitechapel Road  
Whitechapel, E1 1BB  
[pramod.achan@bartshealth.nhs.uk](mailto:pramod.achan@bartshealth.nhs.uk)

**Chevonne Brady**

Royal Free Hospital, London  
[chevonne.brady@gmail.com](mailto:chevonne.brady@gmail.com)

**Dr Sowkhya Ramachandraiah**

Radiology Registrar, Wessex Deanery  
Southampton General Hospital,  
Tremona Road, Southampton, SO16 6YD  
[sowkhya.ramachandraiah@uhs.nhs.uk](mailto:sowkhya.ramachandraiah@uhs.nhs.uk)

**Dr Chandni Patel**

(Radiology Specialty Registrar)  
Royal Surrey County Hospital, Guildford, UK  
[chandni.patel4@nhs.net](mailto:chandni.patel4@nhs.net)

**Dr Sara Zafar**

Specialist Registrar  
Radiology Department  
Chelsea & Westminster Hospital  
369 Fulham Road, London, SW10 9NH  
[sarazafar@nhs.net](mailto:sarazafar@nhs.net)

**Riddhika Chakravartty**

Radiology ST2, Guildford Road  
Chertsey, KY16 OPZ  
[riddhika.chakravartty@nhs.net](mailto:riddhika.chakravartty@nhs.net)

**Dr Charles Peebles**

Consultant Radiologist  
University Hospitals Southampton  
[charles.peebles@uhs.nhs.uk](mailto:charles.peebles@uhs.nhs.uk)



## FOUNDATION YEARS JOURNAL 2018

Volume 12

### Foundation years journal

**Foundation Years Journal** is the ONLY journal for Foundation Years, doctors and educators, specifically written according to the MMC curriculum. It focuses on one or two medical specialties per month and each issue delivers practical and informative articles tailored to the needs of junior doctors. The Journal closely follows the Foundation Years syllabus to provide the best educational value for junior doctors. In addition to good clinical and acute care articles, assessment questions give junior doctors the chance to gauge their learning. Each issue provides comprehensive clinical cases for trainees as well as practical teaching assessments for educators. Readers will benefit from:

- **MMC CURRICULAR-BASED CONTENT** to enhance understanding of the core competencies required from future leading doctors.
- **FOCUS ON SPECIALTY-SPECIFIC CLINICAL CASES** each month to form broad subject coverage.
- **ADDITIONAL IN-DEPTH** good clinical and acute care articles aligned with the case-based discussion assessments.
- **TRAINING GUIDE FOR FOUNDATION YEAR (FY)** educators with proposed clinical cases for teaching sessions.
- **PRACTICAL & INFORMATIVE** articles written by senior doctors & consultants.
- **EXTRA REVISION** with comprehensive assessment. Questions & Picture Quiz.

### Financial statement

The Foundation Years Journal is financed by subscriptions and advertising. The Journal does not receive money from any other sources, and authors are not paid. The decision to accept or refuse an article for publication in the Foundation Years Journal is free from financial considerations and is solely the responsibility of the Editorial Panel and Editor-in-Chief.

### Conflict of interest

The Foundation Years Journal requires that authors disclose any potential conflict of interest that they may have. This is clearly stated in the Journal's published "Guidelines for Authors" ([https://www.123library.org/misc/FYJ\\_Guidelines\\_For\\_Authors.pdf](https://www.123library.org/misc/FYJ_Guidelines_For_Authors.pdf)). The Journal follows the Guidelines against Conflict of Interest published in the Uniform Requirements for Manuscripts Submitted to Biomedical Journals ([http://www.icmje.org/urm\\_full.pdf](http://www.icmje.org/urm_full.pdf)).

### Animal & human rights

When reporting experiments on human subjects, the Foundation Years Journal requires authors to indicate whether the procedures followed were in accordance with the ethical standards of the responsible committee on human experimentation (institutional and national) and with the Helsinki Declaration of 1975, as revised in 2008.

### Informed consent

123library recognises patients' right to privacy. We require Authors to maintain patients' anonymity and to obtain consent to report investigations involving human subjects when anonymity may be compromised. The Journal follows the Guidelines of the Uniform Requirements for Manuscripts ([http://www.icmje.org/urm\\_full.pdf](http://www.icmje.org/urm_full.pdf)). The Foundation Years Journal requires in its Guidelines for Authors a statement from Authors that "the subject gave informed consent".

### Guidelines for authors

The Guideline for Authors can be found on our website at:

<https://www.123library.org/ejournals/foundation-years-journal>.

### How to order foundation years journal

Orders for subscriptions should be made by email ([subscriptions@123doc.com](mailto:subscriptions@123doc.com)) or with a credit card through the 123 Library website ([www.123library.org](http://www.123library.org)). Or by returning the subscription form included in the Journal to:

#### 123Doc Education

72 Harley Street, London, W1G 7HG

**Order online** [www.123library.org](http://www.123library.org)

**Order by email** [subscriptions@123doc.com](mailto:subscriptions@123doc.com)

**Order by phone** 0203 0313 866

### How to advertise in foundation years journal

**Advertising orders and enquiries can be sent to [sabine@123doc.com](mailto:sabine@123doc.com).**

Tel: +44 (0)207 253 4363.

### Photocopying

Single photocopies of single articles may be made for personal use as allowed by national copyright laws. Permission of the publisher and payment of a fee is required for all other photocopying, including multiple or systematic copying, copying for advertising or promotional purposes, resale and all forms of document delivery.

### Electronic storage or usage

Permission of the publisher is required to store or use electronically any material contained in this Journal, including any article or part of an article. Except as outlined above, no part of this publication may be reproduced, stored in a retrieval system or transmitted in any form or by any means, electronic, mechanical, photocopying, recording or otherwise, without prior written permission of the publisher.

### Notice

No responsibility is assumed by the publisher for any injury and/or damage to persons or property as a matter of products liability, negligence or otherwise, or from any use or operation of any methods, products, instructions or ideas contained in the material herein.

Because of rapid advances in the medical sciences, in particular, independent verification of diagnoses and drug dosages should be made. Although all advertising material is expected to conform to ethical (medical) standards, inclusion in this publication does not constitute a guarantee or endorsement of the quality or value of such product or of the claims made of it by its manufacturer.

## OBTAINING JOINT FLUID IN AN EMERGENCY SETTING: A GUIDE FOR ASPIRATING NATIVE JOINTS

G Crate, L Maling, J Relwani

### History

A hot, swollen joint is a common referral to orthopaedics. It is vital that doctors are comfortable with the management of this condition. To help confirm the diagnosis and to treat septic arthritis, it is essential to have a fluid sample via aspiration or washout (1) - the procedure can therefore be therapeutic as well as diagnostic, as it can relieve pressure on the joint.

Before performing the aspiration, it is important to check blood markers (including Full Blood Count, C-Reactive Protein, clotting/INR and urate) and obtain an X-Ray, if possible, prior to the procedure. If there is a joint prosthesis requiring aspiration or washout, this should ideally be done in theatre/ clean environment to increase sterility.

Aspiration should be done cautiously if there is overlying cellulitis to avoid introducing infection into an uninfected joint - only perform it when there is clinical suspicion of joint involvement.

### The Procedure Itself

**Regardless of the joint requiring access, some basic principles apply (2):**

1. Gain consent.
2. Choose the site and identify the anatomical landmarks.
3. Get the patient in a comfortable position with suitable exposure.
4. Ensure that the person performing the procedure is in a comfortable position to aspirate.
5. A pen or needle lid can be used to mark the spot.
6. Prepare the equipment for an sterile procedure, ensuring that all necessary items are available and within easy reach.

- *sterile cleaning spray, such as Betadine or Chlorhexidine (alcohol wipe is not sufficient)*
- *dressing pack*
- *sterile gloves*
- *wide bore needle*
- *20ml syringe (take two)*
- *a dressing*
- *specimen bottles (some hospital laboratories can perform microbiology and cytology on one sample, some will require two separate samples)*

7. Clean the site, apply sterile gloves

- *no touch technique (do not repalpate)*

8. Attach the needle to the syringe and insert briskly into the chosen spot; do not withdraw on the syringe until confirming the position. If no fluid appears then reposition the needle.

- *aspirate fluid until dry*
- *keep the needle stable and replace the syringe*

9. Apply a dressing

- *note the total amount of fluid aspirated, its colour and consistency. Look for telltale signs such as fat globules mixed with blood ( intra-articular fracture), etc.*

10. Send the fluid for Microscopic examination, Culture and sensitivity tests, and crystals- inform the lab to obtain the urgent results as full results can take up to five days. Occasionally, tests for less common organisms such as mycobacterium are also requested.

Infiltration of local anaesthetic is not recommended routinely as it can be antimicrobial (3). However, it is good practice to offer analgesia prior to this procedure.

This article will discuss how to access common joints in an emergency setting, and will cover the specific potential complications.

A good understanding of anatomy is vital to allow for the procedure to be performed correctly. By far the most common to be referred is the knee joint, and this is the one that trainees should be most comfortable performing. However, the other main joints have also been discussed.

### Wrist

The location for access to the wrist joint is on the dorsal aspect just distal to Lister's tubercle - medial to the anatomical snuffbox (4): the 'Crucifixion fossa'. Apply some flexion to the wrist to open the joint up- although placing it in slight extension can aid the finding of the aspiration spot initially.

Aim the needle through towards the volar side of the wrist, angled slightly towards the thumb in order to stay in the joint and avoid hitting the carpal bones (5).

## OBTAINING JOINT FLUID IN AN EMERGENCY SETTING: A GUIDE FOR ASPIRATING NATIVE JOINTS

G Crate, L Maling, J Relwani

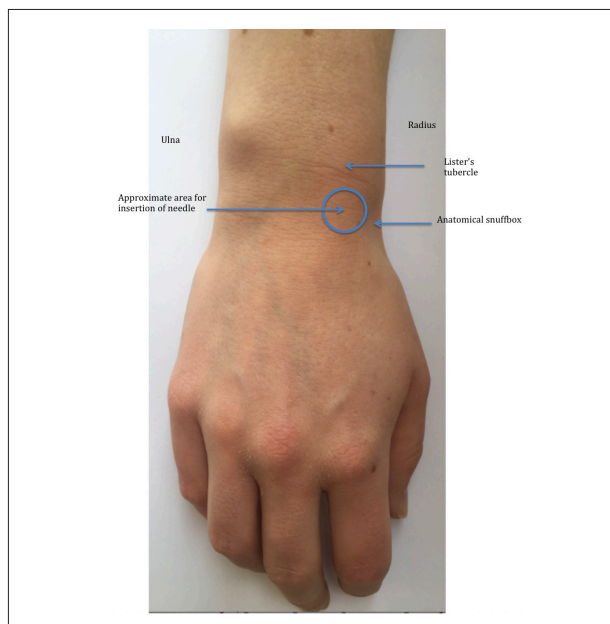


Figure 1

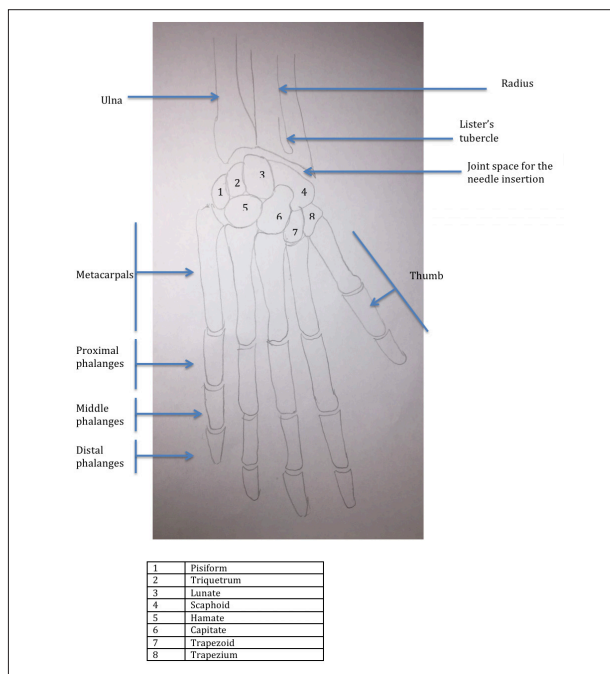


Figure 2

### Complications

- Infection, bleeding, pain, failure

### Elbow

The approach to the elbow is via the lateral side. The area to access the joint is via the soft (anconeus) triangle, which is easier to feel if the elbow is extended (6, 7). This is made up of:

- the lateral border of the olecranon
- the radial head
- the lateral epicondyle

In a swollen elbow, it may not be possible to extend the joint, and the landmarks can be more difficult to palpate. The radial head and olecranon are more accessible in this case. Confirm the bone felt is the radial head by pronating and supinating the forearm whilst palpating it.

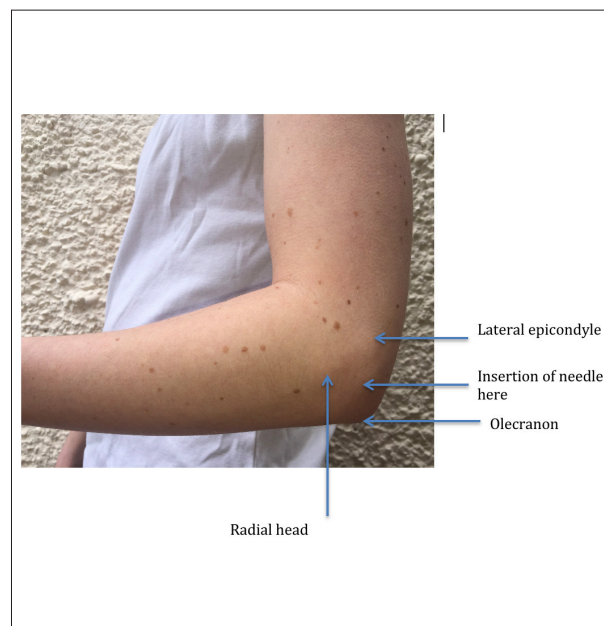


Figure 3

Flex the elbow to 45 degrees and pronate the arm, to help protect the radial nerve (8). Insert the needle into the centre of the triangle and aim for the medial epicondyle (9)

## OBTAINING JOINT FLUID IN AN EMERGENCY SETTING: A GUIDE FOR ASPIRATING NATIVE JOINTS

G Crate, L Maling, J Relwani

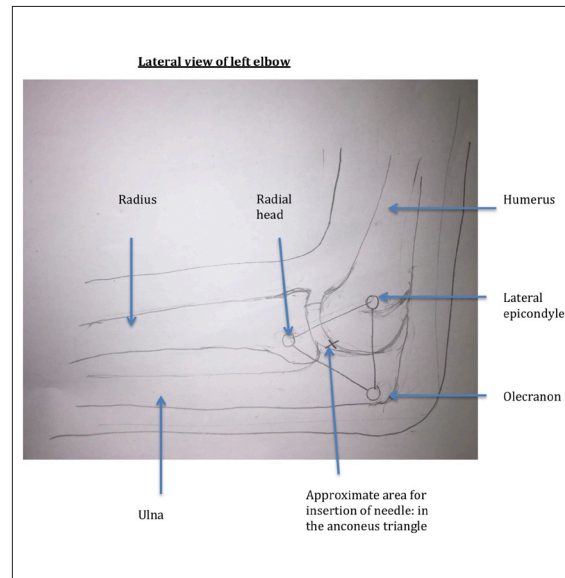


Figure 4

### Complications:

- Infection, bleeding, pain, failure
- Damage to the radial nerve - uncommon as the nerve is located anteriorly at this point.

## Shoulder

### Anterior approach

This approach uses the anterior rotator interval or trans-subscapularis route to enter the shoulder.

### This involves going (10):

- medial to the humeral head
- below the acromion process
- 1cm lateral to the coracoid process

The patient is seated at a 45 degree incline, with the arm supported on a pillow. Palpate the coracoid process and mark a point 1 cm lateral and 1 cm inferior to the tip of the coracoid.

With the elbow at 90 degrees, gently externally rotate the shoulder. Direct the needle perpendicular to the skin in the anteroposterior direction until the bony resistance of the humeral head is met.

The needle passes through the skin, subcutaneous tissue, subscapularis tendon and the glenohumeral capsule to reach the intra-articular humeral head. Once this bony resistance is felt, gently internally rotate the shoulder with the needle in situ, and you will feel that the needle will be carried into the gleno-humeral joint space by the rotation of the subscapularis tendon.

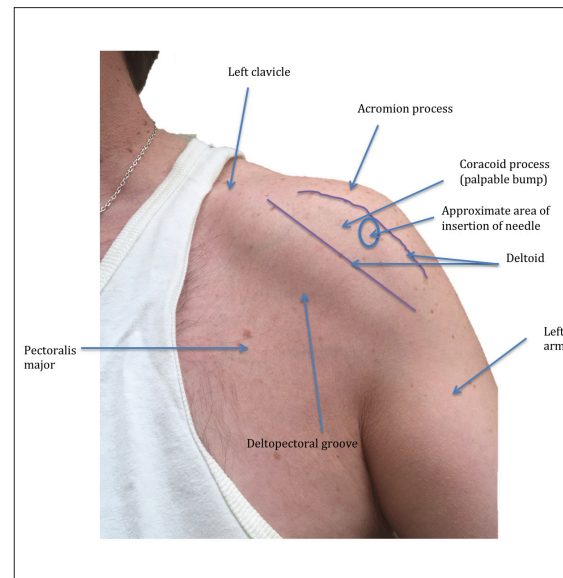


Figure 5

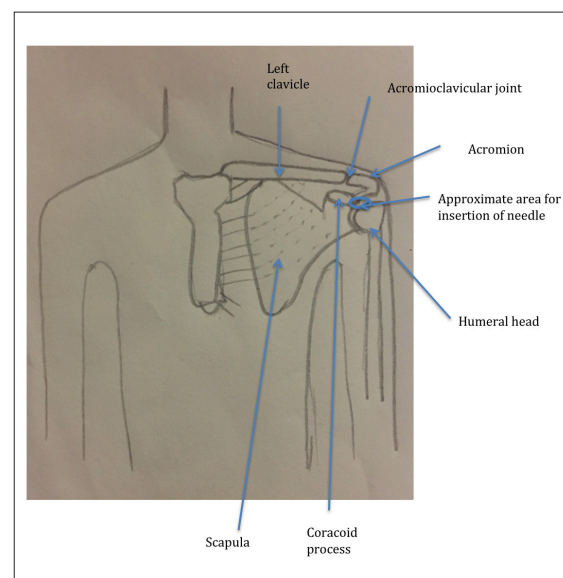


Figure 6

## OBTAINING JOINT FLUID IN AN EMERGENCY SETTING: A GUIDE FOR ASPIRATING NATIVE JOINTS

G Crate, L Maling, J Relwani

Insert the needle horizontally, posteriorly and slightly superolaterally into the joint space (12).

### Posterior approach

Palpate the soft spot of the shoulder 2cm medial and 3cm inferior to the posterior angle of the acromion process. Direct the needle anteriorly and aim to the tip of the coracoid anteriorly to enter the gleno-humeral joint.

### Complications

- Infection, bleeding, pain, failure
- Brachial plexus injury (rare as one is lateral to the coracoid; The lateral side to the coracoid is the 'safe side')

### Ankle

To access the ankle joint the anterolateral (universal) approach should be taken (13). This helps to avoid damage to the deep peroneal nerve as well as the posterior tibial and dorsalis pedis arteries (14).

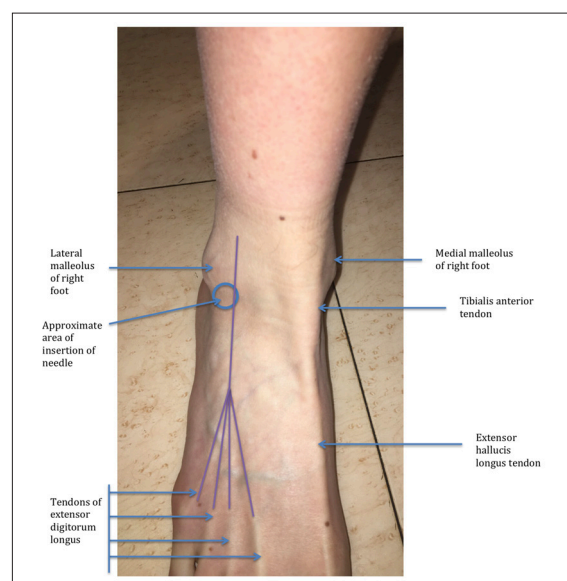


Figure 7

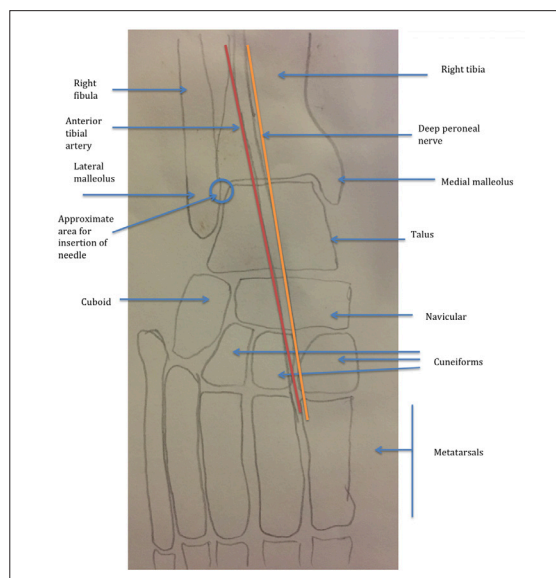


Figure 8

To aid aspiration, flex the knee to 90 degrees and rest the foot on the floor. The entry point is between the lateral border of extensor digitorum longus and the lateral malleolus (15). Direct the needle towards the Achilles tendon and perpendicular to the shaft of the fibula (16).

### Complications:

- Infection, bleeding, pain, failure
- Damage to the deep peroneal nerve
- Damage to dorsalis pedis artery

### NEE

The knee joint can be accessed in three main ways - suprapatellar, parapatellar and infrapatellar (17). The suprapatellar route is one of the more commonly used, as it involves the suprapatellar bursa- however in a percentage of people this bursa does not communicate with the knee joint, making it more difficult- therefore the parapatellar route can be more preferential (18).



## OBTAINING JOINT FLUID IN AN EMERGENCY SETTING: A GUIDE FOR ASPIRATING NATIVE JOINTS

G Crate, L Maling, J Relwani

### Suprapatellar

Feel for the superolateral aspect of the patella. The needle should be inserted approximately 1 finger-breadth superior and 1 lateral to this point, and directed inferomedially underneath the patella (19).

Gently lift up the patella with the opposite hand if possible. This also allows a better judgement of the direction of the needle, which must pass below the patella, heading about 30-45 degrees medially, posteriorly and caudally to enter the joint.

### Parapatellar

This involves inserting the needle just below the midpoint of the patella (lateral or medial side) and aiming towards the intercondylar notch of the femur (20).

With regards to positioning of the knee, extension is best but some slight flexion can relax the quadriceps muscles and open the joint space (21). If the joint has a tense effusion, it is not possible to extend the knee due to the distension of the joint capsule, which keeps the knee in an attitude of flexion.

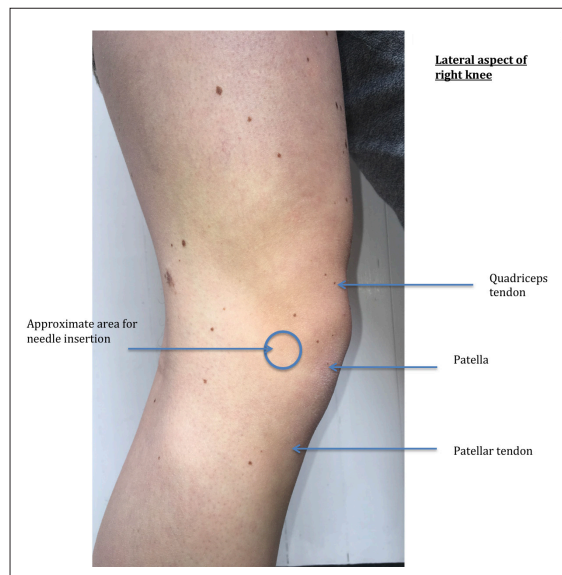


Figure 9

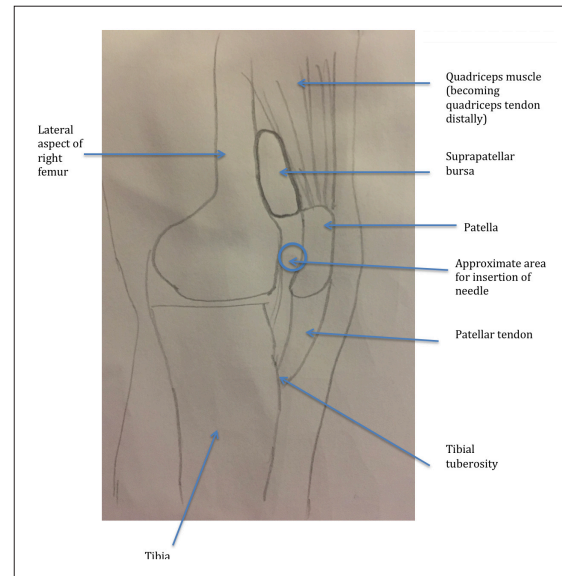


Figure 10

### Complications

- Infection, bleeding, pain, failure

### HIP

Hip aspirations are usually done in theatre with senior support, as they typically require image guidance, generally XR. Arthrography can also be utilised to aid aspiration.

The most frequent approach is anterior-posterior, with the patient lying supine and prepped as previously discussed (22). First palpate the femoral artery- the needle entry should be at least 2cm lateral to this, and along the line of the groin skin crease (23,24).

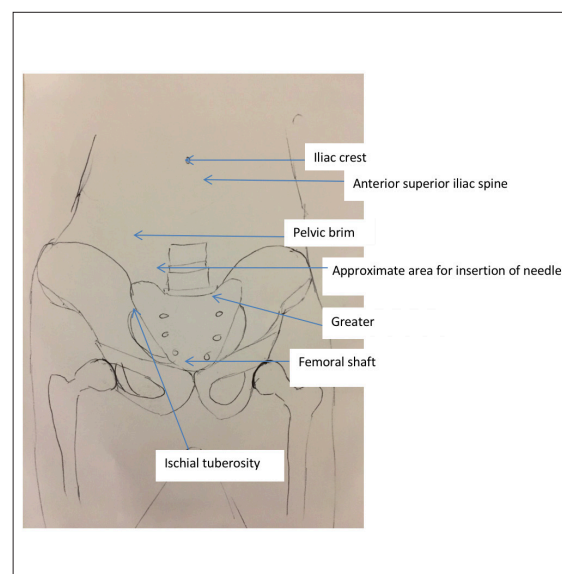


Figure 11



## OBTAINING JOINT FLUID IN AN EMERGENCY SETTING: A GUIDE FOR ASPIRATING NATIVE JOINTS

G Crate, L Maling, J Relwani

Once inserted, the needle is directed towards the medial aspect of the femoral neck as the capsule here is weaker and thus aspiration more straightforward than via the lateral approach (25). This area also tends to be where the majority of fluid collects, too (26).

### Complications

- Infection, bleeding, pain, failure
- Damage to the femoral vessels and nerve

This article is designed as a guide to help junior doctors unfamiliar with aspirations to become more comfortable with the procedure, and provide a reference in emergency situations.

It is not designed as a comprehensive guide, but it covers the joints commonly referred during an orthopaedic on call shift, and provides the junior doctor reader with a quick reference to help enable them to perform the procedures. However, do not be afraid to ask for help from seniors if you require it.

### Authors

#### Georgina Crate

CT1 Trauma and Orthopaedics  
William Harvey Hospital Ashford,  
Kennington Road,  
Ashford, TN24 0LZ

#### Lucy Maling

ST3 Trauma and Orthopaedics  
William Harvey Hospital Ashford,  
Kennington Road,  
Ashford, TN24 0LZ  
lucy.maling@nhs.net

#### Jai Relwani

Consultant Trauma and Orthopaedics  
William Harvey Hospital Ashford,  
Kennington Road,  
Ashford, TN24 0LZ  
jai.relwani@nhs.net

### Corresponding Author

#### Georgina Crate

georgina.crate@nhs.net

### References

1. Ross JJ. Septic Arthritis of Native Joints. *Infectious Disease Clinics of North America*. 2017 Jun;31(2):203-218
2. Medscape. Wrist Arthrocentesis Technique. <https://emedicine.medscape.com/article/80032-technique#c3>
3. Johnson SM, Saint John BE, Dine AP. Local anesthetics as antimicrobial agents: a review. *Surgical Infections*. 2008 Apr;9(2):205-13.
4. Medscape. Wrist Arthrocentesis Technique.
5. Ibid
6. Wheeless Online. Aspiration of Elbow Joint. [http://www.wheelsonline.com/ortho/aspiration\\_of\\_elbow\\_joint](http://www.wheelsonline.com/ortho/aspiration_of_elbow_joint)
7. Sanford SO. Arthrocentesis. Roberts JR, Custalow CB, Thomsen TW, eds. Roberts & Hedges' Clinical Procedures in Emergency Medicine. 6th ed. Philadelphia: Elsevier; 2013. 1075-94.
8. Wheeless Online. Aspiration of Elbow Joint. [http://www.wheelsonline.com/ortho/aspiration\\_of\\_elbow\\_joint](http://www.wheelsonline.com/ortho/aspiration_of_elbow_joint)
9. Cardone DA, Tallia AF. Diagnostic and Therapeutic Injection of the Elbow Region. *Am Fam Physician*. 2002 Dec 1;66(11):2097-2101
10. Diagnostic and therapeutic injection of the shoulder region. *Am Fam Physician*. 2003 Mar 15;67(6):1271-8.
11. Bone and Spine. Shoulder Arthrocentesis. <http://boneandspine.com/shoulder-arthrocentesis/>
12. Partin WR. Emergency procedures. Stone CK, Humphries RL, eds. *Current Diagnosis & Treatment: Emergency Medicine*. 6th ed. New York: McGraw-Hill; 2008. Chap 6.
13. Medscape. Ankle Arthrocentesis Technique. <https://emedicine.medscape.com/article/79956-technique>
14. Ibid
15. Ibid
16. Ibid
17. Medscape. Knee Arthrocentesis Technique. <https://emedicine.medscape.com/article/79994-technique#c2>
18. Ibid
19. Zuber TJ. Knee Joint Aspiration and Injection *Am Fam Physician*. 2002 Oct 15;66(8):1497-1501
20. Medscape. Knee Arthrocentesis Technique.
21. Ibid
22. Hansford BD, Stacy GS. Musculoskeletal Aspiration Procedures. *Seminars in Interventional Radiology*. 2012 Dec; 29(4): 270-285.
23. Ibid
24. Lin HM, Learch TJ, White EA, Gottsegen CJ. Emergency Joint Aspiration: A Guide for Radiologists on Call. *Radiographs: A Review Publication of the Radiological Society of North America*. 2009 Jul-Aug;29(4):1139-58.
25. Malfair D. Therapeutic and Diagnostic Joint Injections. *Radiologic Clinics of North America*. 2008 May;46(3):439-53.
26. Lin HM, Learch TJ, White EA, Gottsegen CJ. Emergency Joint Aspiration: A Guide for Radiologists on Call. *Radiographs: A Review Publication of the Radiological Society of North America*. 2009 Jul-Aug;29(4):1139-58.

### Disclaimers

#### Conflict of interest

The Foundation Years Journal requires that authors disclose any potential conflict of interest that they may have. This is clearly stated in the Journal's published "Guidelines for Authors" ([https://www.123library.org/misc/FY\\_Guidelines\\_For\\_Authors.pdf](https://www.123library.org/misc/FY_Guidelines_For_Authors.pdf)). The Journal follows the Guidelines against Conflict of Interest published in the Uniform Requirements for Manuscripts Submitted to Biomedical Journals ([http://www.icmje.org/urm\\_full.pdf](http://www.icmje.org/urm_full.pdf)).

#### Financial statement

The authors of this article have not been paid. The Foundation Years Journal is financed by subscriptions and advertising. The Journal does not receive money from any other sources. The decision to accept or refuse this article for publication was free from financial considerations and was solely the responsibility of the Editorial Panel and Editor-in-Chief.

#### Patient consent statement

All pictures and investigations shown in this article are shown with the patients' consent. We require Authors to maintain patients' anonymity and to obtain consent to report investigations and pictures involving human subjects when anonymity may be compromised. The Journal follows the Guidelines of the Uniform Requirements for Manuscripts ([http://www.icmje.org/urm\\_full.pdf](http://www.icmje.org/urm_full.pdf)). The Foundation Years Journal requires in its Guidelines for Authors a statement from Authors that "the subject gave informed consent".

#### Animal & human rights

When reporting experiments on human subjects, the Foundation Years Journal requires authors to indicate whether the procedures followed were in accordance with the ethical standards of the responsible committee on human experimentation (institutional and national) and with the Helsinki Declaration of 1975, as revised in 2008.

## MANAGING A PLASTIC SURGERY ON-CALL

C Brady

### Abstract

As foundation doctors, particularly in year 2, you may have chosen a rotation in plastic surgery. As part of this you will be placed on a plastic surgery on call rota. Whilst this can be incredibly interesting and rewarding, it can at times feel unsupported as your senior may be off-site or in theatre.

Medical student teaching in plastic surgery is often limited as it is a niche speciality, however, on your first on call shift you will be asked to initially manage these patients. The take can feel overwhelming and so this brief guide summarises what you need to prioritise and how to initially manage common presentations.

### Introduction – Foundation Doctors and the Plastic Surgery Department

Foundation training is an excellent opportunity for junior doctors to gain exposure to many different medical and surgical specialities before applying for their chosen speciality. Often this covers the larger specialities such as General Surgery, Accident and Emergency and General Practice. Some trainees, however, will rotate through the smaller specialities such as plastic surgery.

In fact, most foundation doctors will have some exposure to the speciality whether it is in dealing with finger lacerations in A+E or seeing skin cancers in the community. It is therefore essential that all foundation doctors have some understanding of the common presentations to our department. Foundation year 2 doctors in a plastic surgery department will likely be part of the on-call rota with core surgical trainees.

As a foundation doctor in year 2 you are expected to “begin to make management decisions as part of their progress towards independent practice” (1).

In a speciality such as plastic surgery where you may have had little or no teaching this can seem daunting. This article looks to provide you with the skills to understand which patients need to be seen first and why, as well as how to competently, initially manage most patients before calling your registrar who may be at home, an hour away.

### Clinical Priorities and Emergencies

The vast majority of presentations in plastic surgery can be managed in a trauma clinic setting and it is important that you understand this to avoid overloading your on-call and to make appropriate use of trauma clinics.

There are some conditions, however, which even if suspected mean you should urgently review the patient or at least ask them to be seen that day/night.

### Presentations Which Need to be Seen NOW

- *Necrotising Fasciitis*
- *Compartment Syndrome*
- *A Devascularised Hand/Digit*
- *An Amputated Digit*
- *A Failing Free Flap*

### Presentations Which Need to be Seen That Day/Night

- *Animal bites*
- *Flexor Sheath Infections*
- *Hand Infections with Tracking or Systemically Unwell*
- *Open Hand Fractures and Dislocations*

The pathology and assessment of these presentations is well documented and so that will not be covered here. For each of these presentations, we will cover some practical tips on what to do before calling your registrar, especially overnight. It is important to remember that you should always ask for senior help any time you feel unsafe or out of your depth. It is also important that you don't feel pressured to consent patients for any procedure you are not happy with.

### Necrotising Fasciitis

- *Take a full history from the patient, if they are able to give one*
- *Examine the area of suspicion and take photographs (use your department camera and make sure you have consent)*
- *Review blood results and ensure a lactate and blood cultures have been taken*
- *Ensure that the patient is being resuscitated appropriately and seek ITU help early*
- *Call your registrar (make sure you have all the above information to hand)*
- *This can only be appropriately treated with prompt debridement*

### Compartment Syndrome

- *May be managed by orthopaedics at your centre so check before accepting the referral*
- *Read through the notes to if they have had recent surgery to the limb*
- *Take a full history from the patient*
- *Examine the area of concern, particularly looking at whether the limb is sensate and has pulses*
- *Remove any tight dressings or casts*
- *Send off basic bloods including a creatinine kinase*
- *Call your senior*

## MANAGING A PLASTIC SURGERY ON-CALL

C Brady

### A Devascularised Hand/Digit

- Call for senior help early
- ATLS approach is essential here
- Ensure patient is nil by mouth
- Full set of bloods and x-ray of the hand/digit
- Your registrar may ask you to call the anaesthetic team which you should do promptly

### An Amputated Digit

- Call your registrar immediately on receiving the referral
- Key points in the history include mechanism and timing of injury, smoking status and how the digit has been stored until now
- Ensure the digit is stored correctly (in moist gauze in a plastic bag, inside another plastic bag filled with ice)
- Make the patient nil by mouth and start IV antibiotics
- Take a full set of bloods and prepare the patient for theatre

### A Failing Free Flap

- Read the operation note and have it to hand before calling your senior
- Ensure the patient is not hypotensive and has a good urine output
- Start IV fluids if not already running
- Examine the flap looking for colour, warmth and Doppler signal
- Take photographs (use your department camera and make sure you have consent)
- Make the patient nil by mouth

Whilst the emergencies can feel overwhelming to deal with whilst your bleep is also alarming, it is important to remember your basic management of any unwell patient, taking an ABCDE approach. If you can call your registrar having done just these few things above it will help improve the patients' outcome and save time when you do call them. A proactive foundation doctor will always do well in any department.

Not all emergency patients will require emergent surgery or immediate discussion with your senior, unless you feel out of your depth. Some admission, such as those below, can be managed by competent foundation doctors with some guidance.

### Animal Bites

- Take a full history from the patient, especially if a dog is involved as this may need to be reported to the police
- Examine the wound and look for any tracking or spreading cellulitis (common in cat bites)
- Wash the wounds thoroughly with at least 1 litre of saline
- Xray to rule out an open fracture
- If the bite is significant or a cat bite, admit for IV co-amoxiclav and elevation
- Consider adding the patient to the next day's trauma list for formal washout
- Nil by mouth from midnight if admitted overnight

### Flexor Sheath Infections

- Take a full history from the patient, paying particular attention to any preceding injury
- Examine the finger looking for Kanavel's Signs (swollen finger, red finger, pain into the palm and pain on passive extension of the finger) as this is what your registrar will ask you
- Take photographs (use your department camera and make sure you have consent)
- Xray to rule out any foreign body
- Admit to hospital for IV antibiotics and elevation
- Nil by mouth from midnight if admitted overnight
- Add the patient to the next day's trauma list for formal washout if symptoms don't resolve with antibiotics and elevation
- If severe infection or delayed presentation may need washed out overnight

### Hand Infections with Tracking or Systemically Unwell

- Take a full history from the patient, paying particular attention to any preceding injury and systemic symptoms
- Examine the hand looking for wounds, examine axillary lymph nodes for lymphadenopathy
- X-ray to rule out any foreign body
- Admit to hospital for IV antibiotics and elevation
- Nil by mouth from midnight if admitted overnight
- Unlikely to need added to a theatre list unless there is a wound which needs debrided

### Open Hand Fractures and Dislocations

- Take a full history from the patient, paying particular attention to the mechanism of injury and tetanus status
- Examine the wound looking for gross contamination, if dislocated ensure digit is neurovascularly intact
- Wash the wounds thoroughly with at least 1 litre of saline
- Xray with 3 views (AP, oblique and lateral)
- Admit to hospital for IV antibiotics and elevation
- Nil by mouth from midnight
- Add the patient to the next day's trauma list for formal washout

## MANAGING A PLASTIC SURGERY ON-CALL

C Brady

These presentations are commonly seen as the FY2 on call, especially overnight, in a plastic surgery department. By understanding their urgency and when to involve your registrar you will appear knowledgeable and dependable when on-call. The purpose of highlighting the above conditions is that they can cause patients to deteriorate quickly and so must be dealt with promptly.

### Common Presentations Which Can Be Seen in Trauma/Hand Clinic

The vast majority of plastic surgery presentations and phone calls you receive will be for patients who can be seen in hand or trauma clinics, depending on your departments set-up. By appropriately booking these patients, they can be seen in daylight hours and you can lessen your load whilst on call. You do not want to be seeing closed fractures and nailbed injuries at 2am every night!

**The following conditions can be booked into your trauma clinic the following day/day after:**

- Closed fractures
- Nailbed Injuries (even with tuft fractures)
- Hand lacerations
- Flexor and extensor tendon injuries
- Wound reviews
- Closed dislocations (if the digit is neurovascularly intact)
- Pyogenic granulomas

In taking these referrals, it is essential to note down the date and mechanism of injury. For closed fractures, ensure that the patient is either buddy strapped or placed in a resting splint by the referring unit. For any open injuries, such as lacerations, ensure that the wound has been washed, that the patient is up-to-date on their tetanus and that they are given a course of oral antibiotics, if it is not a clean wound.

Similarly, if you are the FY2 in A+E or GP, ensure that these things are done prior to referring the patient. On a practical level, if you accept referrals from many hospitals, ensure that all x-rays are image linked to your centre as waiting for or repeating these can dramatically slow down your clinic.

### Conclusion

Being a foundation doctor is challenging and can feel overwhelming at times, but it is also one of the most supported times in your medical career. Seeing or managing patients with plastic surgical conditions can be challenging as most medical schools do not include plastic surgery in the core curriculum.

The aim of this review is to provide foundation doctors with some practical tips on how to manage their first on call (which are normally not included in your department handbook!). Above all, ensure you are safe and working within your competency, no matter what department you are working in.

### Teaching Notes

- *Taking a good history is key in identifying the mechanism of injury in digit amputations, which can indicate the likelihood of replantation success*
- *A low threshold for senior involvement is essential in any case where you feel out of your depth*
- *Any open fracture must be swiftly washed out and managed with intravenous antibiotics*
- *You should have a low threshold for admitting patients for intravenous antibiotics in patients with finger and hand infections*

### Multiple Choice Questions

#### 1. How should you store an amputated digit?

- a. On ice
- b. In a bag in the fridge
- c. Wrapped in damp gauze in a bag, inside a bag filled with ice
- d. It does not need storage

#### 2. Which of these questions could be seen in trauma clinic the next day?

- a. A 70-year-old lady who was bitten by her cat yesterday and no has a swollen hand
- b. A 25-year-old man who trapped his finger in the door and has a nailbed injury
- c. A 10-year-old boy who has a glass laceration to his wrist and a cold, white hand
- d. A 50-year-old lady with an open 5th metacarpal fracture

## MANAGING A PLASTIC SURGERY ON-CALL

C Brady

**3. A patient arrives in the emergency department with a swollen, red, hot finger with pain in their palm and pain when you try to extend their finger. What is the most likely cause?**

- a. Necrotising fasciitis
- b. A flexor sheath infection
- c. A proximal phalynx fracture
- d. Extensor tendon injury

**4. What is the definitive treatment for a patient with necrotising fasciitis?**

- a. Antibiotics
- b. Elevating the limb
- c. IV fluids
- d. Debridement

**5. The nurses have called you at 3am because they are worried that a DIEP (free flap) patient has a low urine output and the flap is starting to feel cold. When should this patient be reviewed?**

- a. On the ward round
- b. Once you have finished seeing a flexor tendon injury in A+E
- c. 6am
- d. Immediately

### Answers

**1. How should you store an amputated digit?**

*c. The digit should never be directly touching ice as this can cause frostbite. So wrapping it in gauze and placing it in an ice bag will keep it cool without this risk.*

**2. Which of these questions could be seen in trauma clinic the next day?**

*b. Nailbed injuries (even with a fracture) can be seen the next day provided the finger is neurovascularly intact.*

**3. A patient arrives in the emergency department with a swollen, red, hot finger with pain in their palm and pain when you try to extend their finger. What is the most likely cause?**

*b. Flexor sheath infections are common presentations in the plastic surgery department and looking for Kanavel's signs is a key aspect of your examination*

**4. What is the best treatment for a patient with necrotising fasciitis?**

*d. The definitive treatment for necrotising fasciitis is debridement of the affected tissue.*

**5. The nurses have called you at 3am because they are worried that a DIEP (free flap) patient has a low urine output and the flap is starting to feel cold. When should this patient be reviewed?**

*d. If a nurse calls you concerned about a free flap you should immediately review this patient. The nurses often look after several of these patients a week so a well trained in what to look out for. A cold, congested or failing flap is an emergency which may need to go back to theatre so you should review the patient immediately.*

### Authors

**Chevonne Brady**

Royal Free Hospital, London  
chevonne.brady@gmail.com

### References

(1) The Foundation Programme, 2018. About...

### Disclaimers

#### Conflict of interest

The Foundation Years Journal requires that authors disclose any potential conflict of interest that they may have. This is clearly stated in the Journal's published "Guidelines for Authors" ([https://www.123library.org/misc/FYJ\\_Guidelines\\_For\\_Authors.pdf](https://www.123library.org/misc/FYJ_Guidelines_For_Authors.pdf)). The Journal follows the Guidelines against Conflict of Interest published in the Uniform Requirements for Manuscripts Submitted to Biomedical Journals ([http://www.icmje.org/urm\\_full.pdf](http://www.icmje.org/urm_full.pdf)).

#### Financial statement

The authors of this article have not been paid. The Foundation Years Journal is financed by subscriptions and advertising. The Journal does not receive money from any other sources. The decision to accept or refuse this article for publication was free from financial considerations and was solely the responsibility of the Editorial Panel and Editor-in-Chief.

#### Patient consent statement

All pictures and investigations shown in this article are shown with the patients' consent. We require Authors to maintain patients' anonymity and to obtain consent to report investigations and pictures involving human subjects when anonymity may be compromised. The Journal follows the Guidelines of the Uniform Requirements for Manuscripts ([http://www.icmje.org/urm\\_full.pdf](http://www.icmje.org/urm_full.pdf)). The Foundation Years Journal requires in its Guidelines for Authors a statement from Authors that "the subject gave informed consent".

#### Animal & human rights

When reporting experiments on human subjects, the Foundation Years Journal requires authors to indicate whether the procedures followed were in accordance with the ethical standards of the responsible committee on human experimentation (institutional and national) and with the Helsinki Declaration of 1975, as revised in 2008.

## UNDERSTANDING THE IMPORTANCE OF THE NEUROVASCULAR STATUS ASSESSMENT IN THE CARE OF PATIENTS WITH PROXIMAL TIBIA FRACTURES

O Hodge, D Woods

### Abstract

Mr X is a 29-year-old gentleman who, whilst working as a bouncer on New Year's Eve, sustained trauma to the left leg and subsequently presented to the emergency department (ED).

His examination and investigations indicated a proximal tibia-fibula fracture for which he underwent two operations in January.

Post-operatively, he developed signs of left-sided foot-drop and although this was recorded to eventually improve, the case draws attention to the importance of completing and documenting early neurovascular assessments in lower limb traumas, since the timing of injuries e.g. pre-operatively or operatively, may have significant medical and legal consequences.

This report presents Mr X's case and uses the discussion to focus on the importance of the neurovascular status assessment in cases of lower limb injury.

### Case history

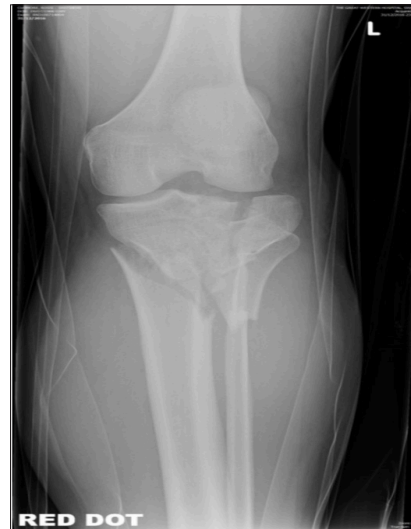#### Presenting complaint and history

Mr X is a 29-year-old gentleman, who presented to the ED on New Year's Eve with severe pain and swelling on the anterior-lateral aspect of his left knee. He explained that whilst working as a doorman that night, he was attempting to break-up a fight when several people involved fell suddenly on his left leg.

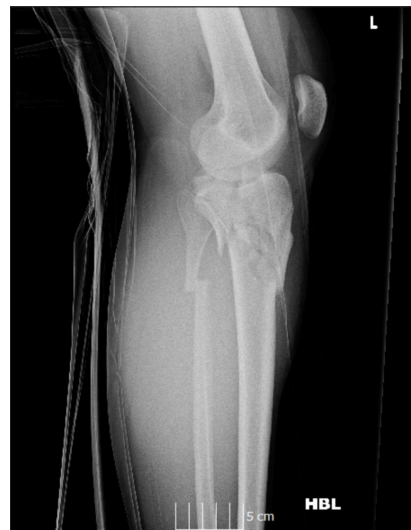He immediately heard a snapping sound, experienced severe pain and had an ambulance called for him. In the ambulance he received morphine for the pain.

Upon initial examination in ED, a large tender swelling was observed in the proximal tibia-fibula region and the overlying skin was intact. The neurovascular status of the distal left leg was documented as 'normal' and the peripheral pulses were present. Upon secondary survey, nil further injuries were identified.

### Investigations



**Figure 1:** A plain AP radiograph of Mr X's left leg, taken hours following his injury. It shows a comminuted intra-articular fracture of the lateral tibial plateau extending into the proximal tibia, with minimal medial translation of the largest distal fragment.



**Figure 2:** The corresponding lateral view radiograph, which shows a simple, transverse fracture of the neck of the fibula with 100% translation inferiorly and a shortening of 5mm. The full radiograph, showed no obvious fracture lines or abnormalities in the femur or the ankle joint.



## UNDERSTANDING THE IMPORTANCE OF THE NEUROVASCULAR STATUS ASSESSMENT IN THE CARE OF PATIENTS WITH PROXIMAL TIBIA FRACTURES

O Hodge, D Woods

**Schatzker gradings.** Mr X's fracture can be described by the Schatzker grading system, which classifies the severity of tibial plateau fractures. The configuration of this fracture is in keeping with a Schatzker grade VI because it involves a metaphyseal-diaphyseal disassociation (1).

### Treatment

#### (a) external fixation

Firstly, Mr X's left leg was placed in a plaster of Paris back-slab and he was referred to the trauma and orthopaedics team. Due to the diffuse swelling in the proximal tibial region, the fractures could not initially be fixed.

However, 24 hours after injury, an external fixator was applied to his leg, with pins in the tibial and femoral shafts to temporarily reduce the fracture.

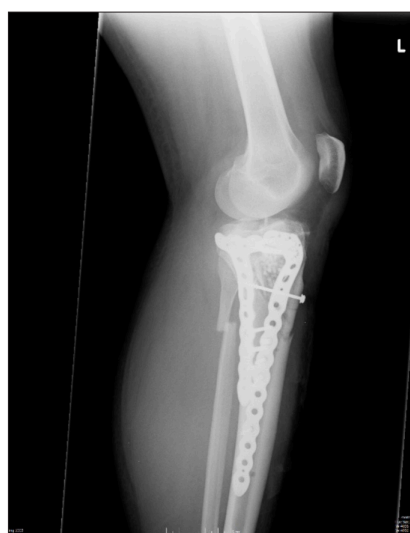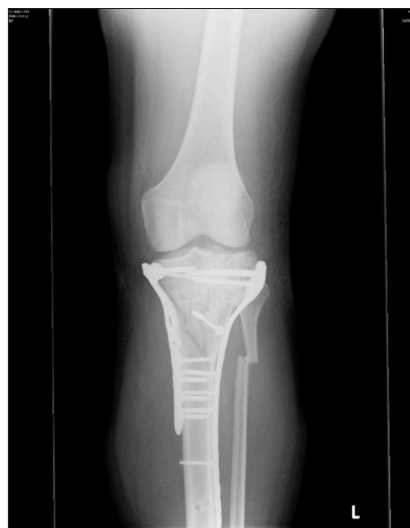Post-operatively, Mr X was monitored for compartment syndrome, given DVT prophylaxis and antiseptic wound care for the external fixator pins.

#### (b) open reduction internal fixation (ORIF)

10 days following injury, the swelling in Mr X's leg had reduced sufficiently for an ORIF operation to take place. This involved the removal of the external fixator before the application of an ORIF with double plating.

The surgical notes reported a compression of the tibial plateau to reduce the intra-articular fracture; use of non-locking and locking screws to fixate the tibial shaft fracture; and a bone graft to replace lost bone in the proximal tibia. In a summarising clinical note, the surgeon recorded a satisfactory overall reduction and fixation of the tibial fractures.

Figures 3 and 4 are the AP and lateral plain radiographs taken of Mr X's left leg 6 days after the ORIF. They show a satisfactory post-operative appearance of the fracture.



**Figure 3 and Figure 4:** Post-operatively, Mr X was monitored for compartment syndrome, given dalteparin, strictly advised to be non-weight bearing on his left leg for 6 weeks and provided with a schedule for regular follow-up appointments to monitor wound healing.

2 weeks following the operation, Mr X was given a high knee brace and referred to physiotherapy with the target of gradually increasing left knee flexion over time.

## UNDERSTANDING THE IMPORTANCE OF THE NEUROVASCULAR STATUS ASSESSMENT IN THE CARE OF PATIENTS WITH PROXIMAL TIBIA FRACTURES

O Hodge, D Woods

### Complications

At his 2-week follow-up review, Mr X complained of pain in his left leg anteriorly. From the documentation it is not clear what precise dermatomes were affected. He was given gabapentin and oxycodone, which effectively managed his pain.

At his 3-week post-operative review, it was reported that Mr X had signs of left foot drop, a sign of damage to the common peroneal nerve, whereby dorsiflexion of the ankle joint is reduced. The clinician advised Mr X to wear a foot splint to ease walking and to prevent the ankle becoming fixed in plantar flexion.

The other complication Mr X experienced was noted, in late February, as an infected medial wound from the left tibial plateau ORIF. In response, the wound was washed out, debrided and monitored regularly over the following months.

### Outcome / update

Mr X was reported to have the full range of left ankle dorsiflexion - indicating a recovery of the common peroneal nerve - by July, 7 months after treatment via ORIF. After multiple problems with scar formation, his scar was recorded as healthy and healed by November.

Figures 5 and 6 are the AP and lateral radiographs taken of Mr X's left leg at his 10-month follow-up clinic. They display an effectively healing fracture with uncomplicated metal work.

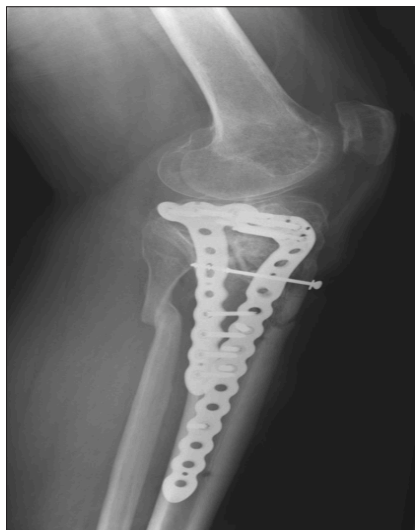

Figure 5

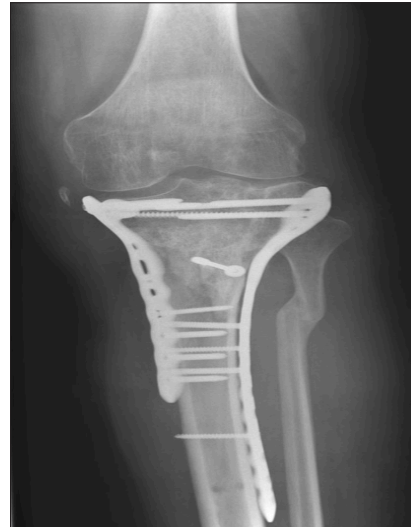

Figure 6

### Discussion

Mr X's radiographs showed a Schatzker VI tibial plateau fracture, which is more frequently associated with higher-energy traumas. It is especially important, in high-energy or crushing lower limb traumas like Mr X's, that a full neurovascular status assessment of the limb is carried out - see figure 7.

In the case of a proximal tibia fracture the assessment is crucial for detecting three injuries associated with long-term morbidity: popliteal artery disruption, compartment syndrome and deep peroneal nerve damage.

Blunt trauma to the lower leg has been associated with a 28% to 46% rate of disruption to the popliteal artery via the mechanism of transection, occlusion or intimal injury (2). On examination of the affected limb, the posterior tibial pulse may be diminished, though this is dependent on the degree of injury (2). Based on the vascular assessment, the clinician must decide whether the extent of popliteal artery damage warrants surgical intervention, since major disruption can be limb-threatening (2).

It is also crucial that compartment syndrome is detected early in the affected lower limb, since failure to recognise and treat it can result in severe ischaemia and significant morbidity (3). Compartment syndrome is a complication of trauma to the lower leg, whereby pressure rises in fascial compartments to compress tissues and restrict blood flow (3).

## UNDERSTANDING THE IMPORTANCE OF THE NEUROVASCULAR STATUS ASSESSMENT IN THE CARE OF PATIENTS WITH PROXIMAL TIBIA FRACTURES

O Hodge, D Woods

During the neurovascular assessment, compartment syndrome should be considered when the patient is experiencing pain out of proportion to the associated injury and pain on passive movement of the muscles in the compartments involved (3). Once diagnosed, the patient should undergo immediate surgery involving the open fascial decompression of the indicated compartments (3).

Furthermore, the thorough documentation of neurovascular status is important for long-term medico-legal reasons. If the patient develops neurovascular complications, such as foot-drop in Mr X's case, documentation can be used to determine the timing and cause of such issues i.e. whether they were caused by the acute injury, developed gradually or were of iatrogenic origin. Such information may be crucial in defending doctors against law suits, whilst the absence of documentation leaves them vulnerable to accusations.

Step-by-step guide to neurovascular observations
<b>Preparation</b>
1. Explain the procedure to the patient and gain his or her consent.
2. Ensure the patient's privacy and dignity are maintained.
3. Ensure that your hands are clean and dry.
<b>Procedure</b>
1. Assess the patient's level of pain using an appropriate pain scale; consider the location, radiation and characteristics of the pain.
2. Palpate the peripheral pulse distal to the injury and/or restriction on the unaffected side, repeat on the affected side and note the presence of the pulse and any inconsistencies between sides in rate and quality of the pulse.
3. If the pulse is inaccessible or cannot be felt, perform a capillary refill test and note the speed of return in seconds on the chart.
4. An assessment of sensation should be made by first asking the patient if he or she feels any altered sensation on the affected limb – consider any nerve blocks or epidurals. Using touch, assess sensation in each of the areas of the foot or hand ensuring all nerve distribution areas are covered. Note any altered sensation on the chart.
5. Ask the patient to flex and extend each toe and/or finger and the ankle and/or wrist, where possible. If the patient is unable to move actively, perform a passive movement. Note any pain reported by the patient either on movement or at rest.
6. Observe the colour of the limb in comparison with the affected side noting any pale, cyanotic or mottled appearance.
7. Feel the warmth of the limb above and below the site of injury using the back of the hand and compare with the other side. Note any excess warmth, coldness or coolness of the limb.
8. Inspect the limb for swelling and compare with the unaffected side. Note whether swelling is moderate or marked, particularly noting any increase since the last set of observations was taken.
<b>Post-procedure</b>
1. Ensure that all documentation is complete including any actions taken. Where deficit is suspected, report to a member of the medical team.
2. Ensure that the patient is left comfortable.

Figure 7: a neurovascular assessment example (4).

Mr X's case exemplifies the importance of performing and accurately recording a thorough neurovascular examination in high-impact lower limb injuries. He was, on three occasions, assessed for compartment syndrome – in ED after his injury and after both operations.

Though absent in Mr X's case, the failure to recognise compartment syndrome in another, similar patient could result in lifelong sensory neuropathy, functional damage to the limb, or the need to amputate; alongside the likely accusation of negligence for the doctor concerned (5).

The initial ED note, which read 'Mr X's neurovascular status is normal,' is important, but its brevity was inappropriate considering the severity of the neurovascular risks associated with proximal tibia fractures.

More extensive documentation of the neurological assessments at the time would make it easier to establish whether Mr X's foot-drop had arisen from his initial trauma or from the operations – a potentially important medico-legal fact. Here, a more detailed, safer note would have referenced the factors listed in figure 7 e.g. the colour, swelling and sensory and motor function of both limbs.

In summary, the regular recording of thorough neurovascular examinations displays good medical practice and care, for patients who have sustained proximal tibia-fibula fractures, or other traumatic injuries to the lower limbs.

Should these patients develop long-term complications, the presence of accurately recorded neurovascular assessments can serve only to improve care, lower litigation rates and protect clinicians against accusations of negligence.

## UNDERSTANDING THE IMPORTANCE OF THE NEUROVASCULAR STATUS ASSESSMENT IN THE CARE OF PATIENTS WITH PROXIMAL TIBIA FRACTURES

O Hodge, D Woods

### Multiple Choice Questions – best of five

The following questions relate to material within the case-based discussion above. They may require some extra reading.

**1. You are a foundation year doctor (FY1) on a night shift in ED. Ms Q has presented with excruciating leg pain having been involved in a car incident, 6 hours previously. On examination, her right lower leg appears misshapen and noticeably swollen.**

**Your colleague asks you to assess Ms Q for compartment syndrome. What common signs and symptoms will you look for?**

- (a) Pain, pallor, paraesthesia, pulselessness and paralysis.
- (b) Pain, erythema and swelling around the fracture site.
- (c) Morning pain alleviated by movement of the joints.
- (d) Saddle and perineal anaesthesia, unilateral leg pain and weakness.

The clinician advised Mr X to wear a foot splint to ease walking and to prevent the ankle becoming fixed in plantar flexion.

**2. Mr H's radiographs show a comminuted intra-articular fracture of the proximal tibia and fibula. As an FY1 you have been asked to review this patient before a plaster-of-Paris cast is fitted as a temporary measure.**

**In your neurovascular assessment, you have ruled out compartment syndrome and deep peroneal nerve damage. What vascular complication, in this case, should also be excluded?**

- (a) Baker's cyst.
- (b) Peripheral artery disease.
- (c) Popliteal artery disruption.
- (d) Superficial femoral artery dissection.
- (e) Varicose veins.

**3. Ms J is a 28-year-old lady who has sustained a proximal tibia-fibula fracture with intra-articular involvement. It is your job, as the FY2, to hand the case over to the orthopaedic registrar. What classification system is commonly used for tibial plateau fractures?**

- (a) Garden classification.
- (b) Weber classification.
- (c) Wassel classification.
- (d) Salter-Harris classification.
- (e) Schatzker classification.

**4. You are an FY1 on duty in the surgical assessment unit. You have been asked to see an 18-year-old man, who underwent an open reduction internal fixation (ORIF) surgery on his right leg 12 hours ago, following a proximal tibia-fibula fracture. He is concerned because he cannot move his right foot and on examination you note he cannot dorsiflex at all. What do you do first?**

- (a) Nothing. Reassure the man that a degree of paralysis is expected after tibial ORIFs; he will soon regain the full movement of his foot.
- (b) Call the surgical registrar on call immediately.
- (c) Organise nerve conduction studies on the man's right and left leg, to be completed in the next 24 hours.
- (d) Immediately contact your senior and record your examination findings – right-sided foot drop – in the patient's notes, alongside further details of the neurovascular assessment. Be thorough and include the time, date and your signature.
- (e) Apologise to the gentleman for the surgical mistakes of your colleagues. Explain to him that he will likely require another surgery to remove the ORIF plates.

**5. You diagnose Mrs G with left-sided foot drop secondary to a proximal tibia-fibula fracture. What nerve has most likely been affected?**

- (a) Sciatic.
- (b) Tibial.
- (c) Common / deep peroneal.
- (d) Superficial peroneal.
- (e) Sural.

## UNDERSTANDING THE IMPORTANCE OF THE NEUROVASCULAR STATUS ASSESSMENT IN THE CARE OF PATIENTS WITH PROXIMAL TIBIA FRACTURES

O Hodge, D Woods

### Multiple Choice Answers

#### 1. (a)

Pain out of proportion to the injury, the need for excessive analgesia, and severe pain on passive movements of the muscles within the compartment. Pain, pallor, paraesthesia, pulselessness and paralysis are no longer taught as the cardinal signs of compartment syndrome. This is because there will typically be no pulselessness, no pallor and no paraesthesia in the early stages of compartment syndrome. Waiting for these signs may delay appropriate management. In cases of saddle and perineal anaesthesia and unilateral or bilateral leg pain and weakness, cauda equina syndrome should be top of your differential diagnoses.

#### 2. (c)

Popliteal artery disruption. Blunt trauma to the lower leg has been associated with a 28% to 46% rate of disruption to the popliteal artery via the mechanism of transection, occlusion or intimal injury. On examination of the affected limb, the posterior tibial pulse may be diminished, though this is dependent on the degree of injury.

Baker's cysts are found in the popliteal fossa but are not vascular problems. They can be described as benign swellings of the semimembranosus or, rarely, another synovial bursa behind the knee joint. They commonly arise not from trauma but from arthritides which affect the knee.

#### 3. (e)

Schatzker classification. The Schatzker grading system classifies the severity of tibial plateau fractures based on factors such as central and lateral plateau depression and metaphyseal-diaphyseal discontinuity.

The garden classification = hip fractures; Weber classification = ankles; Wassel classification = extent of polydactyly; and Salter-Harris classification = fractures involving growth plates.

#### 4. (d)

Immediately contact your senior and record your examination findings – right-sided foot drop – in the patient's notes, alongside further details of the neurovascular assessment. Be thorough and include the time, date and your signature. The regular recording of thorough neurovascular examinations displays good medical practice and care, for patients who have sustained tibia-fibula fractures, or other traumatic injuries to the lower limbs.

Should these patients develop long-term complications, the presence of accurately recorded neurovascular assessments can serve only to improve care, lower litigation rates and protect clinicians against accusations of negligence. Additionally, contacting your senior in a timely fashion is advised, as they may advise loosening the back-slab or other immediate procedures to see if the pressure on the nerve can be relieved.

#### 5. (c)

Common peroneal nerve. The common peroneal nerve is particularly vulnerable to damage in proximal tibia-fibula fractures since it wraps around the neck of the fibula and passes close to the leg surface. Damage to the common peroneal nerve can result in foot drop, whereby an individual is fully or partially unable to dorsiflex their foot.

### Authors

#### Oliver Hodge

Medical Student

Great Western Hospital, Marlborough Road, Swindon, SN3 6BB

#### Mr David Woods

Orthopaedic Consultant

Great Western Hospital, Marlborough Road, Swindon, SN3 6BB

Email: david.woods7@nhs.net

### Corresponding Author

#### Oliver Hodge

Email: oh14776@my.bristol.ac.uk

### References

1. Markhardt K. Schatzker Classification of Tibial Plateau Fractures: use of CT and MRI Imaging Improves Assessment. *RadioGraphics* J 2009;29(2):585-597.
2. Abou-Sayed H, Berger D. Blunt-Lower Extremity Trauma and Popliteal Artery Injuries. *New England Surgical Society* 2002;137(5):585-589.
3. BOAST 10: Diagnosis and Management of Compartment Syndrome of the Limbs. *British Orthopaedic Association Standards for TRAUMA (BOAST)*. 2016. Accessed: 12.12.17.
4. Judge N. Neurovascular Assessment. *Nursing Standard* J 2007;21(45):39-44.
5. Frink M, Hildebrand F, Krettek C, Brand J, Hankemeier S. Compartment Syndrome of the Lower Leg and Foot. *Clinical Orthopaedics and Related Research* 2010;468(4):940-950.

### Disclaimers

#### Conflict of interest

The Foundation Years Journal requires that authors disclose any potential conflict of interest that they may have. This is clearly stated in the Journal's published "Guidelines for Authors" ([https://www.123library.org/misc/FY\\_Guidelines\\_For\\_Authors.pdf](https://www.123library.org/misc/FY_Guidelines_For_Authors.pdf)). The Journal follows the Guidelines against Conflict of Interest published in the Uniform Requirements for Manuscripts Submitted to Biomedical Journals ([http://www.icmje.org/urm\\_full.pdf](http://www.icmje.org/urm_full.pdf)).

#### Financial statement

The authors of this article have not been paid. The Foundation Years Journal is financed by subscriptions and advertising. The Journal does not receive money from any other sources. The decision to accept or refuse this article for publication was free from financial considerations and was solely the responsibility of the Editorial Panel and Editor-in-Chief.

#### Patient consent statement

All pictures and investigations shown in this article are shown with the patients' consent. We require Authors to maintain patients' anonymity and to obtain consent to report investigations and pictures involving human subjects when anonymity may be compromised. The Journal follows the Guidelines of the Uniform Requirements for Manuscripts ([http://www.icmje.org/urm\\_full.pdf](http://www.icmje.org/urm_full.pdf)). The Foundation Years Journal requires in its Guidelines for Authors a statement from Authors that "the subject gave informed consent".

#### Animal & human rights

When reporting experiments on human subjects, the Foundation Years Journal requires authors to indicate whether the procedures followed were in accordance with the ethical standards of the responsible committee on human experimentation (institutional and national) and with the Helsinki Declaration of 1975, as revised in 2008.

## THE MANAGEMENT OF BURSTITIS

KS Khor, P Achan

### Abstract

Bursitis is a common condition which is frequently dealt with by Orthopaedic team either acutely or as a chronic condition. Patients with acute bursitis can present with a collection of pus in the bursa and associated surrounding cellulitis (known as septic bursitis, SB) or non-infected without pus or cellulitis (known as non-septic bursitis, NSB).

This article aims to discuss the incidence, clinical presentation, signs and symptoms and management bursitis of superficial bursae, such as the olecranon, prepatellar and superficial infrapatellar bursae as they are the more commonly affected areas. Management of bursitis is largely conservative, with exceptions in the more refractory case.

### Background

The origin of the word bursa arises from the early 19th century from medieval Latin meaning 'bag or purse'. In physiology, a bursa is a closed synovial-lined thin fluid filled sac formed around musculoskeletal systems. It facilitates smooth gliding between two tissue layers with little friction. (1) (2)

Bursae can be divided into either deep or superficial, according to its location. Deep bursae form in intrauterine life, whereas superficial bursae form in the early months to years following birth, likely stimulated by pressure and friction.(2)

Superficial bursae are prone to repetitive injury due to its location. The olecranon bursa is located over the tip of the olecranon with its boundaries being the skin, proximal subcutaneous border of the ulna and the triceps tendon.

The prepatellar bursa lies directly in the space formed by the anterior aspect of the patellar and skin. It is a separate structure and distinct from the deep and superficial infrapatellar bursae as well as the knee joint itself. The infrapatellar bursa lies between the tibial tuberosity and the skin.

The inflammation of these superficial bursae is commonly seen in clinical practice. They are similar conditions with similar pathology and are often collectively referred to as bursitis and will be discussed as such in this article. The prepatellar and superficial infrapatellar bursitides are usually grouped together as prepatellar bursitis.

Bursitis can present with or without the presence of infection, either acutely through the emergency department whilst oncall, or as a chronic condition through elective outpatient clinic.(3)

Bursitis has a minimum annual incidence of 10/100,000(1) with 1-12/10,000 cases of hospitalisation,(1) however the real incidence of this is unknown due to the presentation to hospital of only the more symptomatic and acute cases.(4) There is an increased male to female ratio of 4:1 presenting with a peak age of 40-60 years old. Approximately two thirds of cases are non-septic bursitis (NSB).(1)

NSB occurs when there is an acute inflammatory response caused by repetitive use or minor trauma and is more commonly seen with certain at-risk occupations or activities. These include carpenters, carpet layers, mechanics, cleaners and athletes(2).

NSB can also occur in patients who have been sitting at a desk for a long period with repeated pressure on the olecranon. As such, olecranon bursitis is sometimes known as student's or minor's elbow'(5) and prepatellar bursitis known as 'housemaid's knee'.

Chronic inflammatory conditions such as rheumatoid arthritis and gout, as well as diabetes mellitus are known to be associated with NSB.

SB is often caused by a bacterial infection of the bursae through localised or direct, rather than haematogenous spread.(1) With any macroscopic or microscopic break in the skin, or in the presence of inflamed tissue, there is an increased chance of soft tissue infection, leading to SB. 80-90% of SB is caused by *Staphylococcus Aureus*, and to a lesser extent by beta-haemolytic *Streptococcus*.

However, in some rare cases, it can be caused by fungi and prototheca algae.(1) Patients who have dermatological conditions such as eczema and psoriatic arthritis with lesions overlying the superficial bursae have a higher propensity to be SB versus NSB.(1)(6)



## THE MANAGEMENT OF BURSTITIS

KS Khor, P Achan

### Clinical Presentation

Patients often complain of a painful red lump either over the patella or olecranon, and if infected, can present with spreading cellulitis. Clinically, it can be difficult to differentiate NSB from SB.(3)

Patients with SB are more likely to have pyrexia more than 37.8 °C and feel systemically unwell. (1)(3) Smith et al published a blinded prospective study which revealed bursal warmth in SB to be 2.2°C greater than the contralateral bursa,(6) although it is important to note that warmth is also a feature in NSB.

When bursae get inflamed, the synovial lining thickens and the potential space fills with more fluid. This inflammatory process causes the clinical picture of swelling, erythema and pain, sometimes with associated reduced flexion secondary to discomfort over the bursae. There is usually a well-defined prominent swelling with marked localised erythema and tenderness.

However, with rupture of the bursa, the swelling can present more diffusely. In the presence of infection or spreading cellulitis, the erythema can sometimes overlie the skin around the entire joint, often triggering a referral to the oncall orthopaedic team to rule out septic arthritis.

### Investigations

Initial investigations includes simple blood tests to check the white cell count as well as C-reactive protein, which would be raised in both SB and NSB, although to different degrees.

Plain radiographs in two orthogonal views are used to rule out any bony injury as well as retained foreign body, which can serve as a nidus for infection and will need to be removed. This is especially important in the cases of trauma or if there are any obvious lacerations overlying the skin.

Bony olecranon spurs are associated with olecranon bursitis. On the plain radiographs, bursitis can be viewed through enhancing the soft tissue shadows by changing the contrast.

An interesting point, although not practical in the context of the NHS and not essential for diagnosis, is that an MRI study was performed by Floemer et al which revealed soft tissue enhancement in 76% of all cases (both SB and NSB). However, they concluded that SB could be excluded in the absence of soft tissue enhancement.(5)

### Treatment

#### Conservative

The treatment for both SB and NSB is largely conservative. Most cases are non-septic and are self-limiting, and therefore the mainstay for treatment is rest, ice, elevate, non-steroidal anti-inflammatories (NSAIDs), and activity modification, especially in patients who have suffered recurrence with at-risk jobs or activities. Splinting to help rest the joint is also useful, for example, a cricket pad splint in the case for prepatellar bursitis, and an elbow extension or a padded splint for olecranon bursitis.

Needle aspiration of the bursa (with or without ultrasound guidance) can also be performed for both diagnostic and therapeutic reasons.(3) Before aspiration, it is important to check with the registrar or consultant oncall as to what their preference is, as needle aspiration is slightly controversial.

It risks spreading infection into a previously sterile bursa and the surrounding previously healthy soft tissue (in the case of NSB)(1) and also risks the formation of a chronically draining sinus tract. There have been studies which have shown that the formation of a sinus has been separate from the entry point of needle aspiration(7) and advocate aspiration as a means of diagnosis and treatment. (1) In confirmed NSB, following aspiration, local injection of corticosteroid is sometimes used.(8)(9)

If there is a suspicion of infection, empirical antibiotic treatment as per local guidelines for cellulitis is recommended. Should there be any systemic features of sepsis, intravenous antibiotics is recommended and admission considered if clinically unwell. Tice et al have shown that patients being treated for SB with oral antibiotics, a single shot of intravenous antibiotics in the Emergency Department increases the intrabursal concentrations of the drug.(10)

#### Surgical

In the more refractory cases despite adequate conservative management, open bursal resection has been explored with complications such as wound breakdown and atrophic skin changes, chronic sinus formation.(8)

In chronic prepatellar bursitis, Quayle and Robinson suggested when performing open debridement of the bursa, the anterior wall of the bursa is preserved and the rest of the bursa is resected without undue risk to the overlying skin and also without an increased risk of recurrence.(11)

The same authors also described with satisfactory results the excision of the olecranon spur if present in the case chronic olecranon bursitis. (12)

## THE MANAGEMENT OF BURSITIS

KS Khor, P Achan

In patients who are critically unwell or immunocompromised, an open debridement and bursectomy can be performed, especially if the source of sepsis is a septic bursitis with a collection of pus. In cases where the skin is threatened due to a large abscess, surgical resection will help reduce the risk of skin necrosis.(1)

For the management of both non-septic chronic olecranon and prepatellar bursitis, resection through an endoscopic approach with no significant complications was described in a study which revealed 86% of 31 cases of olecranon bursitis and 68% of 19 cases of prepatellar bursitis were symptom-free.(13) In fact, it was found to have less morbidity, a faster recovery and better cosmetic result.(14)

### Summary

Treatment for bursitis is mainly conservative, and resolves with adequate rest and short term immobilisation and simple anti-inflammatories medication. For those with at-risk activities/occupations, activity modification or padded splints can reduce recurrence.

Treating the cause such as predisposing medical conditions will help reduce recurrence as well. Needle aspiration or injection of corticosteroids are controversial and advice should be sought from the consultant or registrar on call prior to this. For the refractory cases as well as clinically unwell, there are surgical options.

### Authors

#### KS Khor

Department of Trauma and Orthopaedics,  
Royal London Hospital, Whitechapel Road,  
Whitechapel, E1 1BB.

#### P Achan

Department of Trauma and Orthopaedics,  
Royal London Hospital, Whitechapel Road,  
Whitechapel, E1 1BB.  
pramod.achan@bartshhealth.nhs.uk

### Corresponding Author

#### KS Khor

Suan.khor@nhs.net

### References

1. Baumbach SF, Lobo CM, Badyine I, Mutschler W, Kanz KG. Prepatellar and olecranon bursitis: literature review and development of a treatment algorithm. *Arch Orthop Trauma Surg.* 2014 Mar;134(3):359-70. doi: 10.1007/s00402-013-1882-7. Epub 2013 Dec 5. Review.
2. Zimmermann B 3rd, Mikolich DJ, Ho G Jr. Septic bursitis. *Semin Arthritis Rheum.* 1995 Jun;24(6):391-410. Review.
3. Reilly D, Kamineni S. Olecranon bursitis. *J Shoulder Elbow Surg.* 2016 Jan;25(1):158-67. doi: 10.1016/j.jse.2015.08.032. Epub 2015 Nov 11. Review.
4. McAfee JH, Smith DL. Olecranon and prepatellar bursitis. Diagnosis and treatment. *West J Med.* 1988 Nov;149(5):607-10. Review.
5. Floemer F, Morrison WB, Bongartz G, Ledermann HP. MRI characteristics of olecranon bursitis. *AJR Am J Roentgenol.* 2004 Jul;183(1):29-34.
6. Smith DL, McAfee JH, Lucas LM, Kumar KL, Romney DM. Septic and nonseptic olecranon bursitis. Utility of the surface temperature probe in the early differentiation of septic and nonseptic cases. *Arch Intern Med.* 1989 Jul;149(7):1581-5.
7. Stell IM. Management of acute bursitis: outcome study of a structured approach. *J R Soc Med.* 1999 Oct;92(10):516-21.
8. Aaron DL, Patel A, Kayiaros S, Calfee R. Four common types of bursitis: diagnosis and management. *J Am Acad Orthop Surg.* 2011 Jun;19(6):359-67. Review.
9. Weinstein PS, Canoso JJ, Wohlgethan JR. Long-term follow-up of corticosteroid injection for traumatic olecranon bursitis. *Ann Rheum Dis.* 1984 Feb;43(1):44-6.
10. Ho G Jr, Tice AD. Comparison of nonseptic and septic bursitis. Further observations on the treatment of septic bursitis. *Arch Intern Med.* 1979 Nov;139(11):1269-73.
11. Quayle JB, Robinson MP. An operation for chronic prepatellar bursitis. *J Bone Joint Surg Br.* 1976 Nov;58-B(4):504-6.
12. Quayle JB, Robinson MP. A useful procedure in the treatment of chronic olecranon bursitis. *Injury.* 1978 May;9(4):299-302.
13. Ogilvie-Harris DJ, Gilbert M. Endoscopic bursal resection: the olecranon bursa and prepatellar bursa. *Arthroscopy.* 2000 Apr;16(3):249-53.
14. Huang YC, Yeh WL. Endoscopic treatment of prepatellar bursitis. *Int Orthop.* 2011 Mar;35(3):355-8. doi: 10.1007/s00264-010-1033-5. Epub 2010 Jun 4.

### Disclaimers

#### Conflict of interest

The Foundation Years Journal requires that authors disclose any potential conflict of interest that they may have. This is clearly stated in the Journal's published "Guidelines for Authors" ([https://www.123library.org/misc/FY\\_Guidelines\\_For\\_Authors.pdf](https://www.123library.org/misc/FY_Guidelines_For_Authors.pdf)). The Journal follows the Guidelines against Conflict of Interest published in the Uniform Requirements for Manuscripts Submitted to Biomedical Journals ([http://www.icmje.org/urm\\_full.pdf](http://www.icmje.org/urm_full.pdf)).

#### Financial statement

The authors of this article have not been paid. The Foundation Years Journal is financed by subscriptions and advertising. The Journal does not receive money from any other sources. The decision to accept or refuse this article for publication was free from financial considerations and was solely the responsibility of the Editorial Panel and Editor-in-Chief.

#### Patient consent statement

All pictures and investigations shown in this article are shown with the patients' consent. We require Authors to maintain patients' anonymity and to obtain consent to report investigations and pictures involving human subjects when anonymity may be compromised. The Journal follows the Guidelines of the Uniform Requirements for Manuscripts ([http://www.icmje.org/urm\\_full.pdf](http://www.icmje.org/urm_full.pdf)). The Foundation Years Journal requires in its Guidelines for Authors a statement from Authors that "the subject gave informed consent".

#### Animal & human rights

When reporting experiments on human subjects, the Foundation Years Journal requires authors to indicate whether the procedures followed were in accordance with the ethical standards of the responsible committee on human experimentation (institutional and national) and with the Helsinki Declaration of 1975, as revised in 2008.

## ORTHOPAEDICS: ACUTE COMPARTMENT SYNDROME

N Pakroo, F Wong, J Walczak

### Abstract

Acute compartment syndrome (ACS) is one of the few true emergencies in trauma and orthopaedics. ACS is typically caused by bleeding or oedema within a closed osteofascial compartment, which can lead to high intracompartmental pressure (ICP) and eventually muscle and nerve ischaemia.

It is a limb-threatening and potentially life-threatening condition and therefore carries a high morbidity and mortality.

Prompt recognition of the symptoms with a high index of clinical suspicion is necessary to avoid a late diagnosis. In this article we will explore the pathophysiology, how to identify high risk patients, clinical diagnosis and management of this critical condition.

### Case Based Discussion

An otherwise fit and healthy 35-year old male presents to A&E after falling off his bicycle travelling at high speed.

He complained of pain in his left lower leg and examination shows bruising but no deformity of the lower limb. X-rays confirm a minimally displaced spiral fracture of the right tibia.

The fracture is reduced in A&E and a back-slab is applied.

3 hours later on the ward, the patient is complaining of excessive pain in his leg, particularly on passive dorsiflexion of his forefoot.

### Introduction

Compartment syndrome is an acutely painful condition caused by increased ICP within a closed osteofascial compartment. Compartment syndrome may develop acutely or be chronic.

ACS is a surgical emergency and without intervention will quickly lead to necrosis of the soft tissues with significant morbidity – e.g. muscle contractures leading to permanent deformity and disability - and even mortality. An American study reported a mortality of 47% after ACS of the thigh (1).

ACS typically occurs after serious injuries including crush injuries to the limbs or fractures, but may also be iatrogenic or after a relatively minor injury including vigorous exercise. Most commonly, the leg and forearm are involved but ACS can affect the buttocks, foot and hand.

The average annual incidence of ACS reported have been estimated at 1 to 7.3 per 100,000. It also appears to occur more frequently in males (2). In a retrospective study by McQueen et al, in 164 patients with compartment syndrome, 69% of cases were associated with a fracture, and half of those involved the tibia (3).

### Pathophysiology

Most studies suggest that fractures are the most common cause of ACS and account for 69-75% of cases (4). It is also useful to remember that ACS may occur in both open and closed fractures. Many surgeons assume that due to the nature of an open fracture the osteofascial compartment is naturally decompressed, however there may only be a small fascial tear which is inadequate to decompress the whole compartment.

Soft tissue and vascular injuries in the absence of fractures are also important causes of ACS.

In ACS the initial trauma causes an inflammatory response leading to oedema of the affected compartment. In other circumstances there may be vascular injury causing bleeding into the compartment.

Circulation of blood from high pressure arteries to low pressure veins is dependent on the pressure differential between these vessels termed the arteriovenous gradient ( $\Delta p$ ).

When the  $\Delta p$  gradient reduced, the rate of delivery of arterial oxygenated blood and drainage of deoxygenated venous blood decreases. Reduced venous drainage gives rise to extrusion of fluid into the third compartment, this causes further tissue oedema and exacerbates the ICP rise. This establishes a sequence, leading to the collapse of the lymphatics and ultimately the arterial supply leading to muscle and nerve ischaemia and irreversible necrosis.

Paraesthesia, tingling and nerve symptoms may begin as early as 30 minutes from the onset of ischemia and irreversible damage can occur as early as 12 hours post-onset (5).

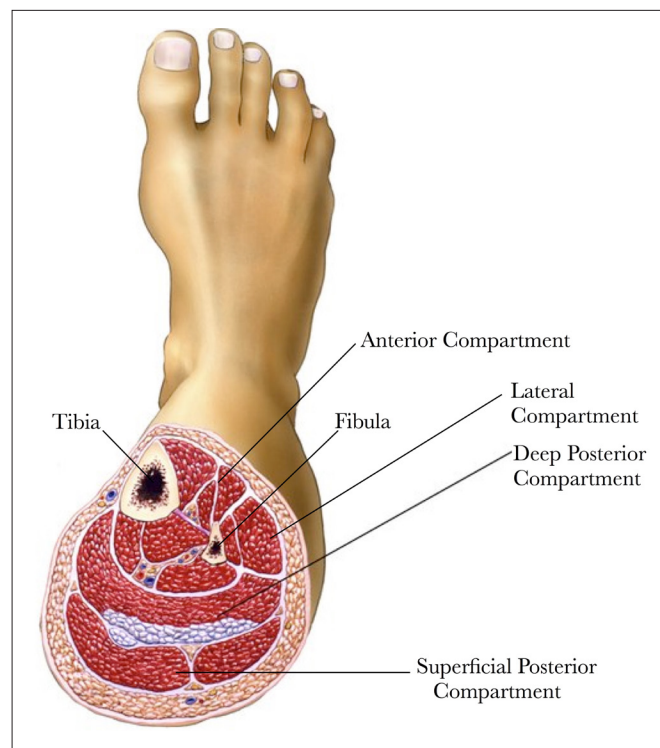
## ORTHOPAEDICS: ACUTE COMPARTMENT SYNDROME

N Pakroo, F Wong, J Walczak

### Anatomy

In both the upper and lower limbs, the muscle groups are arranged in distinct fascial compartments.

In the lower limb, the thigh has 3 osteofascial compartments and the leg has 4. In the forearm there are 4 compartments, 6 in the wrist and 10 in the hand. Acute compartment syndrome can occur in any of these areas. The anatomy of the lower limb is illustrated in figure 1.



**Figure 1: An axial cross-section below the knee, demonstrating the 4 fascial compartments of the lower Leg. Compartment syndrome may occur to increasing pressure in any of the osteofascial compartments. Image modified from NHS Choices (6).**

### History

As with any orthopaedic history, the mechanism of injury is crucial to determine early on in the history taking. High energy mechanism of injury, or history of crush injury should help to alert the clinician to high risk patients. A high index of suspicion in the clinician is key to avoid a missed or delayed diagnosis.

Assessment for a developing acute compartment syndrome should be part of the any evaluation of patients who have sustained significant limb injuries, have had surgery for limb injuries, and any patient after a long surgical procedure which may predispose to hypo-perfusion of a limb.

### When assessing patients with suspected ACS clear documentation should include:

- the mechanism of injury and the time of injury
- time of assessment of the patient
- level of pain (usually scored out of 10)
- level of consciousness (using the Glasgow coma scale)
- response to analgesia and whether a regional anaesthetic has been given (as these may mask symptoms) (7).

### Examination

Every patient with suspected ACS should have a swift A to E assessment.

In order to assess the affected limb, the general look, feel, move approach can be used. Examination should be focused and prompt to avoid pain and discomfort for the patient. All circumferential dressings and casts, including backslab, must be completely split.

**Look:** There may be very few visual signs in early ACS. The patient's limb is likely to be or has been in plaster or a back slab, and they may having swelling distally. In late ACS there may be mottling of the skin, bluish or very pale skin indicating ischaemia.

**Feel:** The patient will be in a great amount of pain, the pulses should be palpated and capillary refill time measured. In late ACS the distal limb may be cold. It must be noted that the presence of a distal pulse is not a useful diagnostic sign for compartment syndrome.

**Move:** The key clinical findings are pain out of proportion to the associated injury and pain on passive movement of the muscles of the involved compartments, e.g. plantarflexion on the foot will cause excessive pain in the posterior compartment syndrome of the lower leg. However, loss of active movement of the foot and toes by the patient can be an earlier sign of Compartment Syndrome.

Limb neurology and perfusion should be assessed but do not contribute to early diagnosis of the condition.

## ORTHOPAEDICS: ACUTE COMPARTMENT SYNDROME

N Pakroo, F Wong, J Walczak

### Investigations

Measurement of elevated compartment pressures are not required for diagnosis if the clinical picture is convincing.

If compartment pressures are being measured these should be taken in both the anterior and deep posterior compartments (for tibial fractures) at the level of the fracture as well as at proximal and distal locations to determine the highest tissue pressure measurement. This measurement should be used to determine the need for fasciotomy (8).

There are several ways of measuring compartment pressure. Commercial devices like the Stryker STIC Device is probably the easiest and most accurate means of measuring compartment pressures on the ward.

Compartment pressures may also be obtained using an angiocath connected to a blood pressure transducer (similar to the set-up of an arterial). Other options for measuring compartment pressures exist but are rarely utilized in clinical practice.

Normal tissue pressure ranges between 0-10 mmHg. Capillary blood flow within the compartment may be reduced at pressures of > 20 mmHg. Muscle and nerve fibers are at risk for ischemic necrosis at pressures >30 to 40mmHg.

Ischaemia however depends on perfusion pressures and these are therefore not absolute values. It can be helpful to compare the compartment pressure to the patient's Diastolic Blood Pressure over time. If the difference between these is less than 30 mmHg for a sustained period (30 minutes or more), compartment syndrome must be suspected. The pressure differential should be interpreted along with the clinical picture.

**Laboratory tests:** Blood tests should be performed in the acute setting and include Full blood count, Urea & Electrolytes, Coagulation screen, Group and save. It may also be of value to check creatinine kinase (CK), as ACS patients are at high risk of rhabdomyolysis.

### Management

Management of confirmed ACS requires rapid action and emergency surgery to prevent long-term muscle damage. Management should involve initial resuscitation followed by ACS specific treatment requiring the input of a senior orthopaedic surgeon.

### 1. Resuscitation

- Follow an A-E assessment of the patient and treat any immediate threats to life.
- Ensure adequate oxygenation and IV access.

### 2. ACS Treatment

- Escalate the patient to seniors and arrange an immediate fasciotomy in theatre.
- Remove all constrictive dressings on the affected limb.
- Elevate the limb to the level of the heart.
- If no improvement in symptoms after 30 minutes, then progress to theatre. British Orthopaedic Association (BOA) guidelines suggests the patient should be in theatre within 1 hour of the decision being made to perform fasciotomies (7).

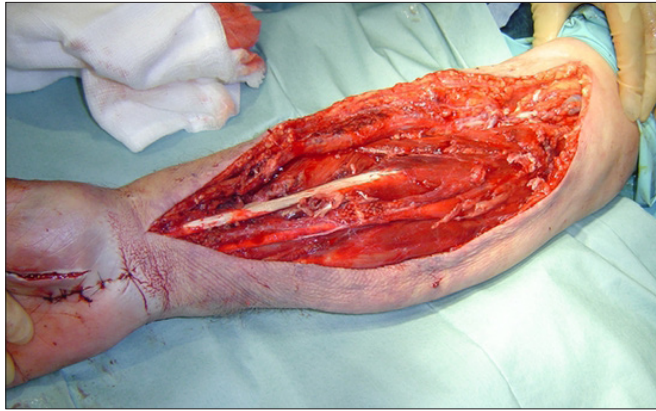When the fasciotomy is performed, the incisions must be large enough to sufficiently decompress all the compartments 9. (see image). Fasciotomy is usually performed in the operating room under general or regional anesthesia.

### Important principles of fasciotomy include:

- an accurate incision of adequate length and depth
- full incision to release the entire constricted compartment
- avoidance of important neurovascular structures
- full debridement of ischaemic and non-viable tissue
- a re-look in the operating room every 24-72 hours after fasciotomy for dressing changes, re-debridement and assessment of tissue viability
- closure of skin (skin grafting may be necessary) within 7 to 10 days (10).

## ORTHOPAEDICS: ACUTE COMPARTMENT SYNDROME

N Pakroo, F Wong, J Walczak



**Figure 2: Fasciotomy with extensile Henry's approach for forearm compartment syndrome (11).**

After emergency decompressive fasciotomies are performed, the surgeon must address the open wounds that have been created. In some circumstances, it is possible to consider primary closure. However, in the majority of cases oedema of the tissues, skin retraction, and presence of potentially non-viable tissue contraindicate this approach.

Closure in the majority of cases is delayed or completed in a staged approach. Some may require the use of split skin grafts and need input from plastic surgeons (12).

### Conclusion

Acute compartment syndrome is critical orthopaedic emergency with potentially devastating consequences if diagnosis is late or missed. ACS can present with various symptoms indicating increased pressure in the affected osteofascial compartment, resulting in muscle and nerve ischaemia and ultimately necrosis.

Diagnosis of ACS can be difficult, which highlights the importance of high clinical suspicion and thorough clinical examination. ICP monitoring when properly utilized can be an objective way to confirm ACS diagnosis in patients who do not have convincing clinical evidence.

Early consultation with an orthopaedic surgeon and decision for fasciotomy is essential to prevent irreversible soft tissue necrosis and limb salvage. Timely intervention can avoid the serious complications of ACS including, limb paralysis, contractures, amputation and even multi-organ failure and death.

### MCQs

#### 1. Compartment Syndrome may occur due to the following events:

- Long bone fracture in a closed osteofascial compartment
- Open fracture
- Crush injury
- Re-perfusion of limb
- All of the above

#### 2. The diagnosis of acute compartment syndrome should be made with:

- Clinical examination
- Compartment pressure measurement
- High index of suspicion
- Correlation to the mechanism of trauma
- All of the above

#### 3. Clinical sign for compartment syndrome includes:

- Pain on examination of the affected limb
- Pain on passive stretching of the muscle in the affected compartment
- Pain not controlled with simple analgesia
- All of the above



## ORTHOPAEDICS: ACUTE COMPARTMENT SYNDROME

N Pakroo, F Wong, J Walczak

### 4. Which one of the following is NOT a sign of compartment syndrome?

- Increased capillary refill time
- Paraesthesia
- Pain that is always relieved by elevation of the affected limb
- Worsening pain, not controlled with analgesia
- Pain on passive stretch of the muscles in the affected compartment

### 5. You suspect compartment syndrome in a 23-year-old male on the ward with a traumatic distal radius fracture. Their arm is in a backslab and he's complaining of severe pain. How should you initially manage this patient?

- Prescribe stronger opioids
- Elevate the limb with a Bradford sling
- Open and release the dressings, split the backslab
- Call the registrar and ask them to review the patient
- Gain IV access and prescribe fluids

## Authors

### Nadia Pakroo

Core Surgical Trainee  
Princess Royal University Hospital,  
Farnborough Common,  
Orpington, Kent, BR6 8ND

### Fabian Wong

Orthopaedic Registrar  
Princess Royal University Hospital,  
Farnborough Common,  
Orpington, Kent, BR6 8ND  
fabian.wong@gmail.com

### Jonathan Walczak

Orthopaedic Consultant  
Princess Royal University Hospital,  
Farnborough Common,  
Orpington, Kent, BR6 8ND  
jonathan.walczak@nhs.net

## Corresponding Author

### Nadia Pakroo

nadiapakrou@doctors.org.uk

## References

- Schwartz JT, Brumback RJ, Lakatos R, Poka A, Bathon GH BA. Acute compartment syndrome of the thigh-a spectrum of injury. *J Bone Jt Surg Am.* 1989;(71):392-400.
- Via AG, Oliva F, Spoliti M, Maffulli N. Acute compartment syndrome. *Muscles Ligaments Tendons J.* 2015;5(1):18-22.
- McQueen MM, Gaston P C-BC. Acute compartment syndrome. Who is at risk? *J Bone Jt Surg Br.* 2000;82(2):200.
- Mauffrey. Acute Lower-leg Compartment Syndrome. *Orthopedics.* 2013;36(8):619-24.
- Mabvuure NT, Malahias M, Hindocha S, Khan W, Juma A. Acute compartment syndrome of the limbs: current concepts and management. *Open Orthop J [Internet].* 2012;6:535-43.
- NHS Choices. Compartment Syndrome. 2016.
- British Association of Plastic and Reconstructive Surgeons, British Orthopaedic Association. British Orthopaedic Association Standards for Trauma BOAST 1 Version 2: Diagnosis And Management Of Compartment Syndrome Of The Limbs. 2012;(December):2016.
- McQueen MM C-BC. Compartment monitoring in tibial fractures. The pressure threshold for decompression. *J Bone Jt Surg Br.* 1996;(78):99-104.
- Taylor RM, Sullivan MP, Mehta S. Acute compartment syndrome: Obtaining diagnosis, providing treatment, and minimizing medicolegal risk. *Curr Rev Musculoskelet Med.* 2012;5(3):206-13.
- Pechar J, Lyons MM. Acute Compartment Syndrome of the Lower Leg: A Review. *J Nurse Pract [Internet].* 2016;12(4):265-70.
- Badge R HM. Forearm Compartment Syndrome following Thrombolytic Therapy for Massive Pulmonary Embolism: A Case Report and Review of Literature. *Case Rep Orthop.* 2012.
- von Keudell AG et al. Diagnosis and treatment of acute extremity compartment syndrome. *Lancet.* 2015;386(10000):1299-310.

## Disclaimers

### Conflict of interest

The Foundation Years Journal requires that authors disclose any potential conflict of interest that they may have. This is clearly stated in the Journal's published "Guidelines for Authors" ([https://www.123library.org/misc/FYJ\\_Guidelines\\_For\\_Authors.pdf](https://www.123library.org/misc/FYJ_Guidelines_For_Authors.pdf)). The Journal follows the Guidelines against Conflict of Interest published in the Uniform Requirements for Manuscripts Submitted to Biomedical Journals ([http://www.icmje.org/urm\\_full.pdf](http://www.icmje.org/urm_full.pdf)).

### Financial statement

The authors of this article have not been paid. The Foundation Years Journal is financed by subscriptions and advertising. The Journal does not receive money from any other sources. The decision to accept or refuse this article for publication was free from financial considerations and was solely the responsibility of the Editorial Panel and Editor-in-Chief.

### Patient consent statement

All pictures and investigations shown in this article are shown with the patients' consent. We require Authors to maintain patients' anonymity and to obtain consent to report investigations and pictures involving human subjects when anonymity may be compromised. The Journal follows the Guidelines of the Uniform Requirements for Manuscripts ([http://www.icmje.org/urm\\_full.pdf](http://www.icmje.org/urm_full.pdf)). The Foundation Years Journal requires in its Guidelines for Authors a statement from Authors that "the subject gave informed consent".

### Animal & human rights

When reporting experiments on human subjects, the Foundation Years Journal requires authors to indicate whether the procedures followed were in accordance with the ethical standards of the responsible committee on human experimentation (institutional and national) and with the Helsinki Declaration of 1975, as revised in 2008.

## EARLY MANAGEMENT OF MAJOR TRAUMA IN THE OLDER ADULT PATIENT

C Richardson, R Wharton, M Pearse

### Abstract

Trauma remains a major cause of death and disability with around 20 000 cases of major trauma per year in England and over a quarter of cases are fatal. Traditionally trauma has been a disease of the young male, however recent data indicates trauma patients are increasing in age with less of a male predominance. We present the case of an elderly female patient who suffered major life-threatening trauma as a result of a high-speed road traffic accident.

The initial management of major trauma is discussed in light of the most recent NICE recommendations for trauma management in the UK. In addition, the unique characterisations of older adults with trauma including co-morbidities, physiological reserve, decreased bone mineral density and polypharmacy are also discussed.

The care of major trauma in the UK was reorganised into major trauma networks in 2012 with regional major trauma centres for the most severely injured patients.

Traditionally trauma has been a disease of the young male. However, recent data from the Trauma Audit and Research Network indicates the age of trauma patients is increasing with less of a male predominance. Adults over the age of 65 now account for >50% of the severely injured patients registered in the database and older major trauma patients have a similar injury severity and distribution of injury to younger patients (1).

The following case illustrates the current management of an elderly major trauma patient and is based on the most recent recommendations from the National Institute for Health and Care Excellence (NICE) on the assessment and initial management of major trauma (2).

### Case Details

The trauma team in a Major Trauma Centre received advance notice from ambulance personnel of the impending arrival of a haemodynamically unstable patient with multiple injuries, a so-called "code red" admission.

#### The patient arrived in the resuscitation room with the following details from the field ambulance team:

*"88-year-old female. Head on RTC, car vs car. Bilateral femur fractures, bilateral tibia/fibular fractures, possible pelvic fractures. RR 18, HR 130, BP 80 systolic, GCS 15"*

Further details of the mechanism of injury were obtained. The patient was an unrestrained rear passenger in a car travelling at 60mph, involved in a head on collision with another car travelling at 30mph. The patient was found by the ambulance crew in the front of the car.

### What should happen next?

This is an elderly major trauma patient who is haemodynamically unstable and requires rapid simultaneous assessment and management from the trauma team using the Advanced Trauma Life Support (ATLS) approach.

The trauma team is led by the Trauma Team Leader, a consultant who is likely to have an A&E, anaesthetic or acute surgical background. Their role is to oversee the trauma call and make key decisions whilst leading the trauma team and taking advice from the relevant specialities involved. The trauma team itself is comprised of a number of doctors from different specialities who are each given a role prior to arrival of the patient.

Typically there is an A&E Registrar who will complete the primary survey and Senior House Officers from surgical specialities who will order imaging, gain intravenous access and send blood samples. There will be members of the anaesthetic team and a Theatre OPD who are responsible for management of the airway. Senior members of the Trauma and Orthopaedic and General Surgical Teams will be present to provide acute management advice for traumatic injuries and be able to take the patient to theatre urgently if required. Additionally there will be a porter, a radiographer for portable imaging in the Resuscitation room and a radiologist to complete a bedside ultrasound scan and report CT images if required.

As our patient is haemodynamically unstable the trauma team will extend to include a haematologist and the haematology laboratory for blood products. Finally there needs to be a scribe to document the trauma call in real time.

### Foundation doctors and the trauma team

The involvement of a Foundation Doctor in the trauma team is actively encouraged and tasks such as being the scribe and obtaining IV access are a great place to start.

We recommended you introduce yourself to the Trauma Team Leader at the start of a shift and volunteer to take on these roles. Familiarisation with your hospital's trauma team makeup and operational policies is essential before joining the Trauma Team on treating a shocked patient.

## EARLY MANAGEMENT OF MAJOR TRAUMA IN THE OLDER ADULT PATIENT

C Richardson, R Wharton, M Pearse

### How would you assess this patient?

Assessing the patient in an ABCDE manner is paramount as life threatening injuries such as airway compromise or a tension pneumothorax must be excluded first. Unless the primary survey suggests a life threatening limb injury, the limbs should only be examined once the patient is haemodynamically stable as part of the secondary survey.

The patient's airway was patent and she was talking normally. There was bilateral air entry throughout the chest with palpable crepitus on the right anterior chest wall, suggestive of an underlying injury. Oxygen saturations were not recordable, possibly because the patient was cold with a temperature of 32.6 degrees Celsius. Blood pressure was initially 85/60, heart rate 125 and she was centrally mottled with a capillary refill time of 3 seconds.

Her abdomen was soft and non-tender and a pelvic binder was in situ. Whilst the patient was being assessed, wide-bore IV access was obtained, blood was taken for analysis and cross-matching and she received 1 unit of packed red cells immediately on arrival in the emergency department because of the hypotension.

Both lower legs were already immobilised in bilateral traction splints. The Glasgow Coma Scale (GCS) was 15/15.

First venous blood gas result: Hb 78, pH 7.03, lactate 6.1, Base Excess -13.9, glucose (14).

### How would you proceed?

No direct intervention is currently required for her airway or breathing, but continuing problems include hypotension, acidosis and hypothermia. Our patient needs further fluid resuscitation because of probable blood loss from multiple long bone fractures.

In addition, bleeding from other sites such as the chest, abdomen and pelvis have not been definitively excluded. Active warming is also indicated.

### What is the management of a haemodynamically unstable patient?

The trauma team aims for early identification of bleeding and rapid effective haemostasis, whilst providing volume resuscitation and protection of the body's ability to form stable blood clots. The monitoring of blood loss is particularly important in elderly patients who have decreased physiological reserve and an increased risk of an ischaemic cardiac event.

Patients with major open limb trauma may need simple dressings applied with direct pressure to control external haemorrhage or a proximal tourniquet if direct pressure fails to control life threatening haemorrhage. A purpose-made pelvic binder is routinely applied by ambulance staff until pelvic trauma has been excluded.

All hospitals have major haemorrhage (or transfusion) protocols to ensure the rapid delivery of blood components to bleeding trauma patients. Physiological criteria are used to assess the response to volume resuscitation, titrating the volume of resuscitation to maintain the central circulation until stable control is achieved. For adults, a ratio of 1 unit of plasma to 1 unit of red blood cells is recommended to replace fluid volume, and crystalloids are not routinely used for patients with active bleeding (3).

A restricted approach to volume resuscitation may be adopted during active bleeding. This involves accepting a lower blood pressure to reduce bleeding, whilst avoiding diluting the blood's clotting ability from high volume resuscitation. However, if a major traumatic brain injury is present restrictive volume resuscitation may be avoided to ensure cerebral perfusion is maintained.

Haemostatic agents such as intravenous tranexamic acid are given as soon as possible in patients with major trauma and active or suspected active bleeding to directly inhibit clot breakdown (2). Interventional radiology may be considered for patients with active pelvic, spleen, liver or kidney haemorrhage after a multi-disciplinary discussion with the members of the trauma team.

Avoidance of the 'lethal triad' is essential in all trauma patients. This is a self-perpetuating cycle of hypothermia, acidosis and coagulopathy that will rapidly lead to death in the absence of appropriate and prompt intervention (4).

Our patient received a further unit of packed red cells and 2 units of fresh frozen plasma and rapidly became haemodynamically stable. Her temperature improved to 35.5 degrees Celsius. A repeat blood gas after the first unit of blood revealed Hb 110, pH7.32, lactate 2.3, Base Excess -5.6, glucose 14.6

### What investigations would you request?

A whole-body CT scan is indicated in adults with blunt trauma and suspected multiple injuries, particularly if they have suspected haemorrhage which is responding to resuscitation.

More limited diagnostic imaging, such as chest and pelvis x-rays or focused assessment with sonography for trauma (FAST scan), may be needed for suspected haemorrhage in the presence of haemodynamic instability which is not responding to volume resuscitation.

## EARLY MANAGEMENT OF MAJOR TRAUMA IN THE OLDER ADULT PATIENT

C Richardson, R Wharton, M Pearse

Adult patients with severe respiratory compromise may require immediate chest x-ray as part of the primary survey in order to assess for chest trauma. Additionally, radiographs of clinically suspected limb injuries will be needed when the patient is fully stable to evaluate the fractures and to plan surgical management.

### Our patient had a CT scan which revealed the following injuries:

1. Bilateral 1st rib fractures and a right pneumothorax
2. Acute lower pole kidney laceration
3. Right scapula fracture
4. Bilateral humeral head fractures
5. Closed right radius/ulna fracture
6. Open right distal femur fracture
7. Open left distal femur fracture
8. Open right mid shaft tibia fracture
9. Stable Right C7 and T1 transverse process fractures
10. Stable T10 anterior body fracture

### What interventions does this patient require?

Immediate priorities include a chest drain for the right pneumothorax and an arterial line to monitor blood pressure. Fortunately, our patient remained haemodynamically stable after fluid resuscitation, despite her age and multiple injuries and she did not demonstrate signs of respiratory compromise.

### How would you examine the lower limbs?

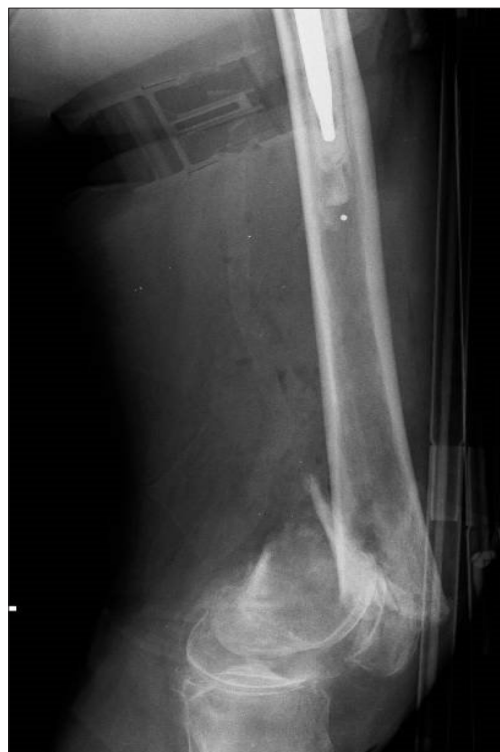The limb examination is part of the secondary survey, which is performed when the patient is stable and usually after preliminary investigations. Both lower limbs were initially immobilised in traction splints. These provide longitudinal traction to maintain length and alignment and prevent damage from unstable limb fractures.

Limb splints also provide pain relief and removing the splints to thoroughly examine the limbs during the secondary survey will be painful; the patient must be given adequate analgesia before splint removal, which is performed by two clinicians.

The lower limbs had obvious clinically deformities in keeping with the whole-body CT scan findings. There were traumatic wounds at each open fracture site. The dorsalis pedis and posterior tibialis pulses were easily palpable bilaterally and there was normal sensation and motor power in both lower limbs. The leg wounds were photographed and then dressed with saline soaked gauze and impermeable dressings, and the clinical findings were recorded.

Wounds associated with open fractures do not require lavage in the emergency department, although gross contamination may be removed. The lower limbs were then immobilised in plaster of Paris backslabs. The open fractures of both lower limbs require management according to the British Orthopaedic Association Standards for Trauma (BOAST) for Open Fractures (5), which includes prompt administration of broad spectrum intravenous antibiotics.

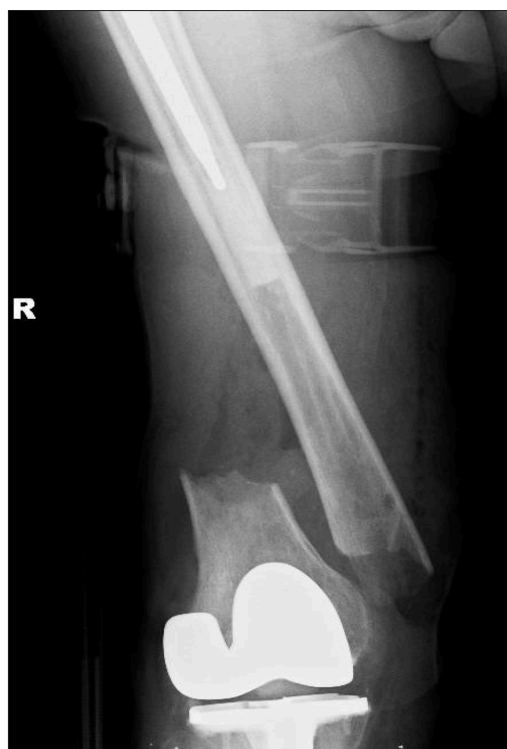Examination of the upper limbs revealed tenderness and reduced motion at both shoulders and an obviously deformed and painful right forearm. The neurological and vascular examinations were normal.



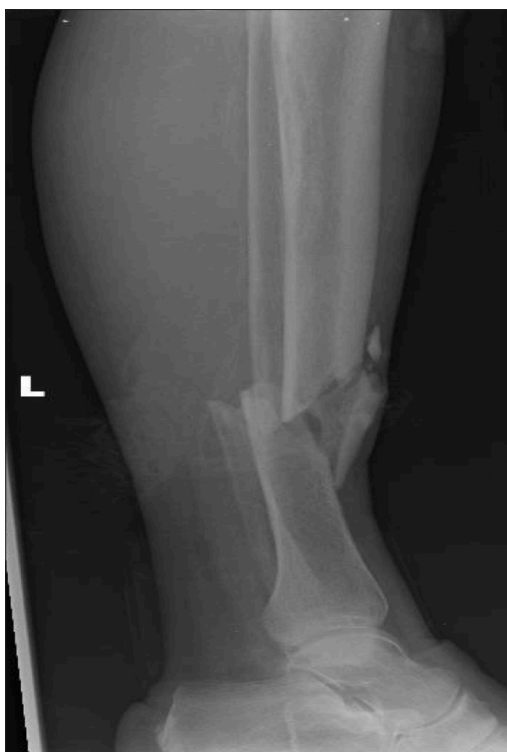**Figure 1: Radiograph of left femur demonstrating a lower shaft fracture distal to a hip replacement.**

## EARLY MANAGEMENT OF MAJOR TRAUMA IN THE OLDER ADULT PATIENT

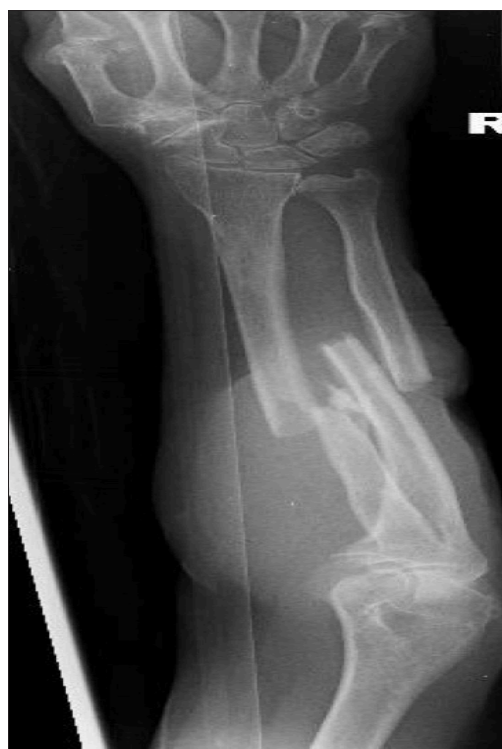C Richardson, R Wharton, M Pearse



**Figure 2:** Radiograph of right femur demonstrating a lower femur fracture distal to a hip replacement and proximal to a total knee replacement.



**Figure 3:** Lateral radiograph of the left tibia demonstrating a mid-shaft fracture.



**Figure 4:** Radiograph of the right forearm showing unstable mid-shaft radius and ulna fractures.

### What further clinical information is required?

Once the patient was haemodynamically stable with splinted and dressed limb injuries, an 'AMPLE' history was taken. This is a brief history of five key questions which obtains important details about the patient's medical history and when they last ate in case an anaesthetic is required (see Table 1).

The AMPLE history is usually quick to obtain and should be done early on as the mental state of the patient may deteriorate. For our patient this revealed that they had no allergies, took metformin for type 2 diabetes and was not on antiplatelet or anticoagulation drugs. Additionally she had bilateral hip replacements and a right total knee replacement.

Knowledge of existing implants is important as it will affect the implant options when planning fracture fixation. An Abbreviated Mental Test Score should also be obtained in the older adult; it is useful to have a baseline score as there is risk of delirium in the post-injury or post-operative period.

## EARLY MANAGEMENT OF MAJOR TRAUMA IN THE OLDER ADULT PATIENT

C Richardson, R Wharton, M Pearse

### Allergies

### Medications

### Past Medical History

### Last meal (when did the patient last eat?)

### Events (can the patient recall what happened?)

**Table 1. A trauma team member obtaining an AMPLE history can be of value if there is a change in mental state**

The medical and drug histories are especially important in the older adult trauma patient as they are more likely to be on multiple medications, which can pose further challenges. Anticoagulation and antiplatelet drugs increase the likelihood of intracranial haemorrhage following trauma and may also compromise spinal anaesthesia if surgery is required (6).

The existing co-morbidities together with the pre-accident mobility status are relevant when planning interventions, establishing ceilings of care and gauging rehabilitation potential.

### What are the principles of surgery in major trauma?

Urgent surgical intervention is indicated for life threatening injuries. Definitive orthopaedic surgeries, such as fracture fixation should only be carried out when the patient is stabilised and normal homeostasis has been restored as defined by the following parameters: pH >7.25, lactate <4, Base excess <-5.5 (7).

Mobile long bone fractures carry a risk of fat embolism to the lungs and can be an ongoing source of haemorrhage and pain. Our patient was reviewed by consultant orthopaedic and plastic surgeons, together with the anaesthetic team and an appropriate management plan was formulated.

As our patient remained stable, wound debridement and closure and temporary skeletal stabilisation with external fixators to the lower limb fractures was undertaken on the day of injury.

Temporary fixation of long bone fractures with external fixation is known as "damage control" and definitive fixation is performed later when the patient is fully stable.

### Case Outcome

As a result of the prompt care received at the Major Trauma Centre, our patient survived significant life and limb threatening injuries. The multi-disciplinary trauma team delivered early blood product resuscitation and haemorrhage control with con-current identification and treatment of the injuries.

Following skeletal stabilisation with external fixators, the patient had definitive internal fixation of all the long bone limb fractures on day 4 post-injury. She made a satisfactory recovery and was later discharged to a rehabilitation unit.

### Diminished physiological reserve

### Comorbidities – especially ischaemic heart disease, diabetes, COPD

### Polypharmacy – especially anticoagulants and anti-platelets

### Cerebral atrophy leading to diminished brain volume and higher risk of subdural haemorrhage

### Possibility of elder maltreatment/abuse

### Decreased bone mineral density – higher fracture risk and surgical complexity

### Increased likelihood of joint replacement surgery with associated risk of dislocation (hips)

**Table 2: Considerations in the elderly patient with major trauma**

### Multiple Choice Questions

#### 1. The lethal triad consists of the following:

- Hyperthermia, acidosis and coagulopathy*
- Hypothermia, acidosis and hypovolaemia*
- Hypothermia, acidosis and coagulopathy*
- Hypothermia, acidosis and tachycardia*
- Hypothermia, alkalosis and coagulopathy*



## EARLY MANAGEMENT OF MAJOR TRAUMA IN THE OLDER ADULT PATIENT

C Richardson, R Wharton, M Pearse

### 2. Which of the following statements is true of the immediate management of the haemodynamically unstable trauma patient

- a. Immediate damage control surgery
- b. Rapid crystalloid IV infusion
- c. Early identification of bleeding, effective haemostasis whilst providing volume resuscitation and protection of the body's ability to form stable blood clots
- d. Take an AMPLE history
- e. Consider triggering the massive transfusion protocol

### 3. Which of the following patients should be managed as a trauma patient?

- a. 80yo female falls from standing whilst walking to church. She is suspected to have a neck of femur fracture
- b. 85yo male tripped on the stairs at home. He is complaining of pain in his chest and pelvis.
- c. 70yo male is hit by a car at 20mph whilst crossing the road
- d. 68yo female hits her head on the sofa when falling at home. She is on Warfarin.
- e. All of the above

### 4. What is the investigation of choice in an adult patient presenting after blunt trauma?

- a. Skeletal survey
- b. FAST scan
- c. Early chest x-ray
- d. Whole body CT scan
- e. Interventional radiology

### 5. Which of the following may adversely affect the outcome in an elderly patient with major trauma?

- a. Comorbidities – especially ischaemic heart disease, diabetes, COPD
- b. Decreased bone mineral density – higher fracture risk and surgical complexity
- c. Polypharmacy – especially anticoagulants and anti-platelets
- d. Diminished physiological reserve
- e. All of the above

### Answers

#### Option c:

The lethal triad is hypothermia, acidosis and coagulopathy. Preventative measures are immediately instigated and include warming blankets and the use of warmed IV fluids.

The correct ratio of packed red cells / fresh frozen plasma / platelets must be followed according to the local major transfusion protocol and clotting is monitored by serial testing. Tranexamic acid is also administered early.

#### Options c & e:

Trauma patients should be managed using an ATLS approach and each step completed before moving to the next step. A haemodynamically unstable patient requires large bore intravenous access and rapid transfusion with blood products, which may require activation of the massive transfusion protocol if initial resuscitation measure do not lead to haemodynamic stability and multiple blood units are needed.

The patient should also receive tranexamic acid and the source of bleeding sought and controlled; think the 'floor and four more' – the floor (what blood loss was there at the scene?), chest, abdomen, pelvis and long bones.

#### Option e:

The commonest mechanism of injury for older adults with trauma is a fall of <2m, which can cause life threatening major trauma. Have a low threshold for suspecting injuries and assess patients thoroughly.

Rib fractures are common after falls and can result in significant morbidity and mortality from hospital acquired pneumonia and respiratory failure if not identified and treated early.

Patients sustaining major trauma initially presenting to a local Trauma Unit should be managed in liaison with the local Major Trauma Centre (via the Trauma Team Lead) who may advocate expeditious transfer.

## EARLY MANAGEMENT OF MAJOR TRAUMA IN THE OLDER ADULT PATIENT

C Richardson, R Wharton, M Pearse

### Option d:

*A patient presenting following blunt trauma requires a whole body CT scan. Injuries such as liver and spleen lacerations can be sustained from blunt trauma but easily missed clinically until the patient is in extremis.*

*A whole body CT scan is also valuable when there are other reasons injuries may be missed, these include a distracting injury causing the patient pain, intoxication and impaired mental state.*

### Option e:

*Elderly patients with major trauma should be approached in the same way as young adult trauma patients. However special consideration needs to be given to factors relating to their medical health that may influence or challenge management.*

*Decreased bone mineral density can result in significant fractures from low level trauma and therefore vigilance is required when looking for injuries. Co-morbidities and diminished physiological reserve mean that early resuscitation with blood products, and careful continued fluid balance is even more important.*

## Authors

### Mr Michael Pearse

1 St Mary's Hospital,  
Imperial College Healthcare NHS Trust  
London  
W2 1NY

### Miss Charlotte Richardson

1 St Mary's Hospital,  
Imperial College Healthcare NHS Trust  
London  
W2 1NY  
charlotte.richardson@doctors.org.uk

### Mr Rupert Wharton

2 Northwick Park Hospital,  
London North West University  
Healthcare NHS Trust  
Harrow  
HA1 3UJ  
rupert.wharton@nhs.net

## Corresponding Author

### Mr Michael Pearse

m.pearse@imperial.ac.uk

## References

1. The Trauma Audit & Research Network (TARN). Major Trauma in Older People, England and Wales. 2017.
2. National Institute for Health and Care Excellence (NICE). Major trauma: assessment and initial management. Feb 2016.
3. Glen J, Constanti M and Brohi K. Assessment and initial management of major trauma: summary of NICE guidance. *BMJ* 2016;353:i3051.
4. Mitra B, Tullio F, Cameron P, et al. Trauma patients with the 'triad of death'. *Emerg Med J* 2012;29(8):622-625.
5. The Association of Anaesthetists of Great Britain & Ireland, The Obstetric Anaesthetists' Association, and Regional Anaesthesia UK. Regional Anaesthesia and Patients with Abnormalities of Coagulation. Nov 2013.
6. British Orthopaedic Association & British Association of Plastic, Reconstructive & Aesthetic Surgeons. Open Fractures, Audit Standards for Trauma. December 2017.
7. Scalea TM, Boswell SA, Scott JD, et al. External fixation as a bridge to intramedullary nailing for patients with multiple injuries and with femur fractures: *Damage Control Orthopedics*. *J Trauma* 2000 Apr;48(4):613-21

## Disclaimers

### Conflict of interest

The Foundation Years Journal requires that authors disclose any potential conflict of interest that they may have. This is clearly stated in the Journal's published "Guidelines for Authors" ([https://www.123library.org/misc/FYJ\\_Guidelines\\_For\\_Authors.pdf](https://www.123library.org/misc/FYJ_Guidelines_For_Authors.pdf)). The Journal follows the Guidelines against Conflict of Interest published in the Uniform Requirements for Manuscripts Submitted to Biomedical Journals ([http://www.icmje.org/urm\\_full.pdf](http://www.icmje.org/urm_full.pdf)).

### Financial statement

The authors of this article have not been paid. The Foundation Years Journal is financed by subscriptions and advertising. The Journal does not receive money from any other sources. The decision to accept or refuse this article for publication was free from financial considerations and was solely the responsibility of the Editorial Panel and Editor-in-Chief.

### Patient consent statement

All pictures and investigations shown in this article are shown with the patients' consent. We require Authors to maintain patients' anonymity and to obtain consent to report investigations and pictures involving human subjects when anonymity may be compromised. The Journal follows the Guidelines of the Uniform Requirements for Manuscripts ([http://www.icmje.org/urm\\_full.pdf](http://www.icmje.org/urm_full.pdf)). The Foundation Years Journal requires in its Guidelines for Authors a statement from Authors that "the subject gave informed consent".

### Animal & human rights

When reporting experiments on human subjects, the Foundation Years Journal requires authors to indicate whether the procedures followed were in accordance with the ethical standards of the responsible committee on human experimentation (institutional and national) and with the Helsinki Declaration of 1975, as revised in 2008.

## HIP JOINT PAIN IN YOUNG, ACTIVE PATIENTS

PG Robinson, P Gaston

### Abstract

Hip pain is a common presenting complaint in musculoskeletal medicine. However, the young adult with hip pain can present a diagnostic challenge. We present a case of a young, active adult with hip pain and discuss the history, examination, investigation and referral to the appropriate specialist.

### Case Report

A 22 year-old female student hockey player presented to the orthopaedic clinic with pain in the left groin. The pain started 6 months previously when she was lunging for a ball (left foot forward) during a match for her university team. She felt a sharp pain at the time but was able to continue playing the rest of the game.

The acute pain settled over the next day. Since the incident she described intermittent deep, catching groin pain during hockey training, forcing her to stop playing. She can no longer perform squats in the gym due to the pain. On further questioning she reported a sensation of clicking in her groin during exercise but denied any radiation of the pain or locking of her hip joint.

The patient had no past medical or childhood hip disorders such as developmental dysplasia of the hip or slipped capital femoral epiphysis and no previous surgery to the left hip. She denied any use of medications including steroids. She was a non-smoker with minimal alcohol intake.

### What to do next?

After taking a thorough history it would be appropriate to examine this lady's hip using the following focused method:

#### Look

- Assess gait (*antalgic*)
- Scars
- Muscle wasting/*asymmetry*
- Leg rotation and length

#### Feel

- Palpate the following structures for tenderness:
  - Anterior superior iliac spine
  - Greater trochanter
  - Abductors, adductors and rectus femoris
  - Ischial tuberosity (*while patient prone*)
- Assess for inguinal hernia

#### Move

- Assess internal and external with the hip in neutral and in 90 degrees of flexion (*compare to the other side*)
- Assess hip flexion and extension
- Assess abduction and adduction

#### Special Tests

- **FADIR Test:** Flexion, adduction and internal rotation of the hip - if this is painful it suggests impingement and possible acetabular labral damage.
- **McCarthy's test:** With both hips flexed, abducted and externally rotated the injured leg is rapidly extended out straight - this assesses internal snapping of the hip (from the psoas tendon).
- **Thomas' Test:** With both hips flexed, one hand is placed under the lumbar spine to ensure it is flat to bed, then each leg is lowered in turn - if the lumbar spine doesn't flatten it indicates a tight anterior capsule, suggesting osteoarthritis.
- **Ludloff's test:** The patient sits bolt upright with their legs extended in front at 90 degrees to their body. They lift each leg straight in turn - pain suggests a hip flexor (psoas muscle) problem, but it can also come from an acetabular labrum tear being put under pressure by the psoas muscle.
- **Trendelenburg test:** An assessment of abductor function. While standing on the injured leg, the pelvis will sag down on the other side if positive.

## HIP JOINT PAIN IN YOUNG, ACTIVE PATIENTS

PG Robinson, P Gaston

### Differential Diagnosis

At this stage, the most likely differential diagnosis is femoroacetabular impingement syndrome, with a labral tear. However, a list of differential diagnoses to consider can be seen in table 1.

An effective way to categorise the diagnoses is by dividing it into intra-articular and extra-articular pathology.

#### Extra-articular

- Snapping hip
- Iliotibial band (external snapping)
- Psoas Tendon (internal snapping)
- True hernia or Sportsman's hernia ('Gilmour's Groin' – strain of the insertion of rectus abdominis at the pubis)
- Adductor muscle strain/tear
- Neuropathic
- Sciatic
- Lateral cutaneous nerve of the thigh
- Obturator nerve irritation
- Piriformis syndrome
- Abductor muscle strain/tear
- Trochanteric bursitis
- Referred pain from lumbar spine

#### Intra-articular

- Labral tear
- Femoroacetabular impingement syndrome
- Osteochondral defect
- Developmental dysplasia of the hip
- Avascular necrosis of the hip
- Stress fracture of the femoral neck
- Osteoarthritis
- Septic arthritis

**Table 1: Differential diagnosis of a painful hip in a young active patient.**

### Investigations

#### Plain radiograph

- Anteroposterior radiograph of both hips (often called an 'AP Pelvis') with both lower limbs internally rotated by 15 degrees (shows the superolateral femoral head/neck junction in profile to assess for bony prominence ('Cam impingement'). It also assesses prominence of the anterior acetabular rim ('crossover sign', 'pincer impingement')
- Horizontal beam lateral of hip joint (shows the anterior femoral head/neck junction in profile to assess for bony prominence ('Cam impingement'))

#### Cross sectional imaging

- MRI arthrogram of the affected hip, with injection of gadolinium contrast prior to the scan. This shows soft tissue damage, including labral damage

**NB:** if you have any suspicion that the patient's hip pain may be due to septic arthritis, then a full septic screen work up should be performed and discussion with the on-call orthopaedic registrar prior to starting antibiotics.

## HIP JOINT PAIN IN YOUNG, ACTIVE PATIENTS

PG Robinson, P Gaston

### Referral

If you see a patient with hip pain as described here in the emergency department it may be appropriate to refer them to the orthopaedic registrar on call for consideration of orthopaedic out-patient follow up. If the patient was seen in a general orthopaedic clinic, a referral should be made to the local young adult hip specialist for further assessment. Because of the unfamiliarity of most doctors with the causes of hip/groin pain in young adults, it often takes up to 2 years or more for patients to see a specialist.

### Femoroacetabular Impingement Syndrome

#### What is it?

Femoroacetabular impingement syndrome (FAI) is a movement related clinical disorder of the hip characterized by a triad of symptoms, clinical signs and imaging findings (1).

It is characterized by painful, clicking or catching deep in the groin with a restricted range of movement, or a positive impingement test (FADIR) as well as radiographic findings of cam or pincer morphology on plain radiographs.

#### What is the cause?

The cause of FAI is relatively unknown. It is thought to be caused by repetitive, supraphysiological motion at the hip joint, which results in abnormal contact between the femoral head/neck junction and the rim of the acetabulum (1).

Pre-pubertal, vigorous activity leading to an asymptomatic, partially slipped upper femoral epiphysis may play a role in the aetiology.

#### How is it diagnosed?

The number of patients identified with FAI has risen dramatically in the past 10 years (2). The diagnosis requires all three of 1) symptoms 2) clinical signs and 3) radiographic findings.

#### Symptoms

- Hip/groin pain
- Clicking
- Catching
- Locking
- Stiffness
- Giving way

### Clinical signs

- Restricted internal rotation and hip flexion
- Anterior impingement test positive (FADIR Test)

### Radiographic findings

#### Plain Radiographs

- CAM morphology
- Pistol grip deformity
- The prominent bump at the anterosuperior head/neck junction which give the femoral neck the appearance of a pistol.
- Alpha angle >55 degrees
- On axial views – an angle between a line from the centre of the femoral head through the centre of the femoral neck and where the contour of the femoral head-neck junction exceeds the radius of the femoral head
- Head-neck offset ratio <0.17

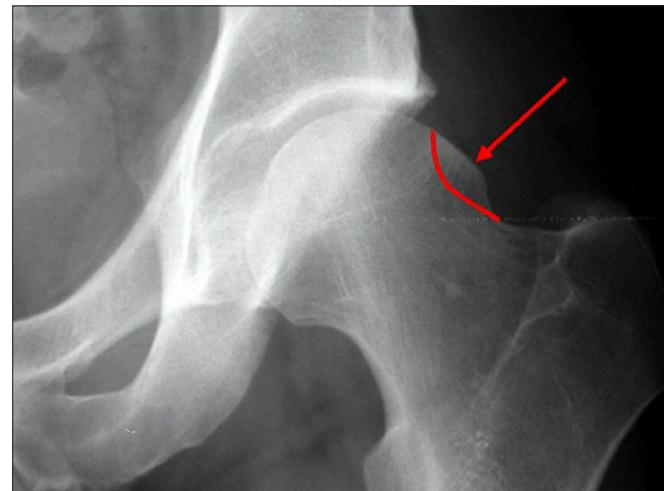
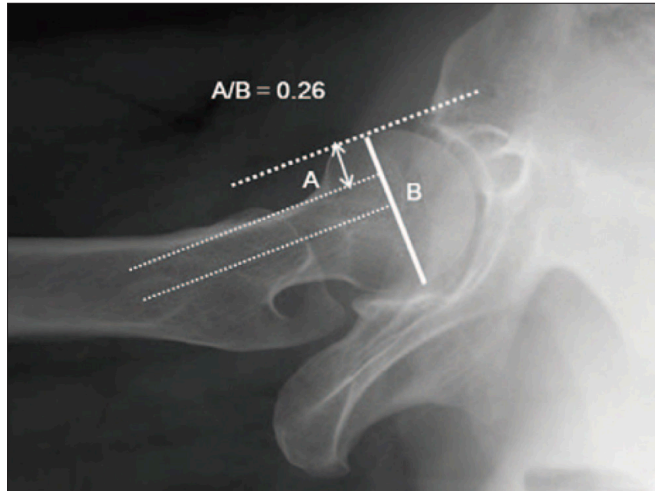


Figure 1: CAM morphology seen on plain radiograph.

## HIP JOINT PAIN IN YOUNG, ACTIVE PATIENTS

PG Robinson, P Gaston

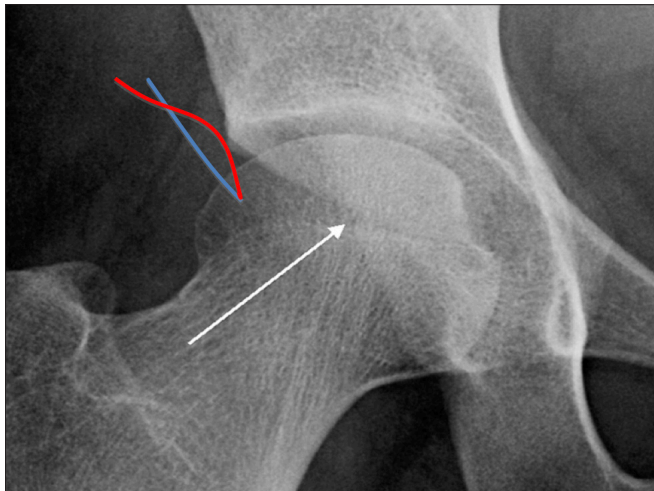


**Figure 2: Lateral radiograph demonstrating the calculation of head-neck offset ratio.**

- Pincer Morphology

- Positive crossover sign

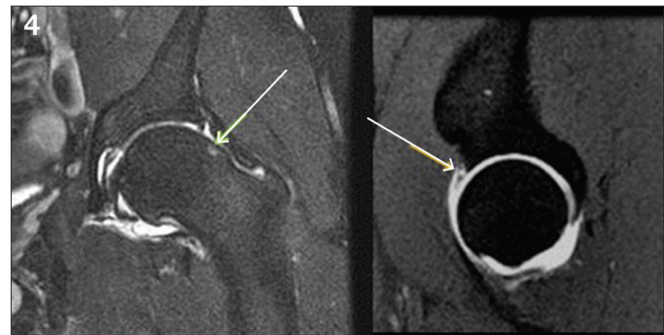
- This indicates prominence of the anterior wall which appears more lateral than the posterior wall and therefore they cross over on an AP radiograph.



**Figure 3: Pincer morphology and crossover sign seen on AP radiograph. (Anterior wall - red, posterior wall - blue)**

### MRI Arthrogram

- Labral tears
- Articular cartilage lesions



**Figure 4: Anterior acetabular labral tear seen on MRI arthrogram.**

### CT scan

- 3D reconstruction can delineate the exact bone shape and prominence of the femoral head/neck junction and acetabular rim.

### How is it treated?

The options for treatment include 1) conservative care 2) rehabilitation or 3) surgery. At present, there is no high level evidence to guide the choice of treatment.

The decision on treatment should be made on an individual basis assessing function, radiological findings and the patient's view of 'disability' – i.e. how restricted they are by the problem.

### Conservative

The basis of conservative management is similar to that of hip osteoarthritis and involves lifestyle modification, analgesia (including non-steroidal anti-inflammatories) and intra-articular steroid injections. This may be appropriate for patients with little pain and no mechanical symptoms.



## HIP JOINT PAIN IN YOUNG, ACTIVE PATIENTS

PG Robinson, P Gaston

### Rehabilitation

This is focused around physiotherapy, with the goal to achieve greater neuromuscular control and movement patterns as well as improved hip mobility (2).

### Surgery

**Surgery can be performed open or arthroscopically. It often involves two main objectives;**

- 1) Restoring bony anatomy by reshaping/removing the CAM and pincer morphology and
- 2) addressing any labral tears which may involve resection, repair or reconstruction of the labrum.

**NB:** Patients who receive surgery are likely to receive both preoperative and postoperative physiotherapy.

### What is the prognosis?

It is thought that most patients with true FAI who do not receive treatment will often experience deterioration in their symptoms over time (3).

Some studies have shown certain patients will improve with physiotherapy alone (4, 5), however there is growing evidence that surgery improves symptoms for at least 5 years (6).

The progression to osteoarthritis following the diagnosis of FAI is currently unknown. However, there does appear to be some association between femoral head CAM morphology and osteoarthritis (7, 8).

### Summary

There are a variety of intra and extra-articular causes of hip pain, which are worth considering when examining patients in both the emergency department and the out-patient clinic. The diagnosis of these pathologies will often require specialist orthopaedic review but early recognition and referral of hip joint pain can help accelerate this process.

### MCQs for Foundation Year Journal Article

#### 1. Which symptom(s) can be caused by femoroacetabular impingement syndrome?

- a. Clicking
- b. Locking
- c. Giving way
- d. Groin pain
- e. All the above

#### 2. What 'special test' on examination is most likely to illicit pain associated with femoroacetabular impingement syndrome?

- a. FABER Test
- b. Thomas' Test
- c. FADIR Test
- d. Trendelenburg Test
- e. McCarthy's Test

#### 3. Which investigation is most sensitive for detecting a hip labral tear?

- a. AP pelvis radiograph
- b. Lateral femoral neck radiograph
- c. CT hip
- d. MRI arthrogram hip
- e. Bone isotope scan

## HIP JOINT PAIN IN YOUNG, ACTIVE PATIENTS

PG Robinson, P Gaston

### 4. Which of the following is an extra-articular cause of hip pain?

- a. Femoroacetabular impingement syndrome
- b. Trochanteric bursitis
- c. Osteoarthritis
- d. Osteochondral defect of the femoral head
- e. Septic arthritis

### Answers

1: e

2: c

3: d

4: b

### Authors

#### Mr Patrick G Robinson

ST2 Trauma & Orthopedics  
Royal Infirmary of Edinburgh  
51 Little France Crescent  
EH16 4SA

#### Mr Paul Gaston

Consultant Orthopaedic Surgeon  
Royal Infirmary of Edinburgh  
51 Little France Crescent  
EH16 4SA  
paul.gaston@ed.ac.uk

### Corresponding Author

#### Mr Patrick G Robinson

patrick.robinson321@gmail.com

### References

- Griffin DR, Dickenson EJ, O'Donnell J, et al. The Warwick Agreement on femoroacetabular impingement syndrome (FAI syndrome): an international consensus statement. *Br J Sports Med* 2016;50:1169-1176.
- Colvin AC, Harrast J, Harner C. Trends in hip arthroscopy. *J Bone Joint Surg Am* 2012;94:e23.
- O'Donnell JM. Femoroacetabular impingement: what happens (in the short term) with no treatment? *St Georges Park, UK: Sports Hip*, 2016.
- Wall PD, Fernandez M, Griffin DR, et al. Nonoperative treatment for femoroacetabular impingement: a systematic review of the literature. 2013;5:418-26.
- Emara K, Samir W, Motasem el H, et al. Conservative treatment for mild femoroacetabular impingement. *J Orthop Surg (Hong Kong)* 2011;19:41-5.
- Wall PD, Brown JS, Parsons N, et al. Surgery for treating hip impingement (femoroacetabular impingement). *The Cochrane Library*, 2014.
- Agricola R, Waarsing JH, Arden NK, et al. Cam impingement of the hip: a risk factor for hip osteoarthritis. *Nat Rev Rheumatol* 2013;9:630-4.
- Agricola R, Heijboer MP, Bierma-Zeinstra SM, et al. Cam impingement causes osteoarthritis of the hip: a nationwide prospective cohort study (CHECK). *Ann Rheum Dis* 2013;72:918-23.

### Disclaimers

#### Conflict of interest

The Foundation Years Journal requires that authors disclose any potential conflict of interest that they may have. This is clearly stated in the Journal's published "Guidelines for Authors" ([https://www.123library.org/misc/FYJ\\_Guidelines\\_For\\_Authors.pdf](https://www.123library.org/misc/FYJ_Guidelines_For_Authors.pdf)). The Journal follows the Guidelines against Conflict of Interest published in the Uniform Requirements for Manuscripts Submitted to Biomedical Journals ([http://www.icmje.org/urm\\_full.pdf](http://www.icmje.org/urm_full.pdf)).

#### Financial statement

The authors of this article have not been paid. The Foundation Years Journal is financed by subscriptions and advertising. The Journal does not receive money from any other sources. The decision to accept or refuse this article for publication was free from financial considerations and was solely the responsibility of the Editorial Panel and Editor-in-Chief.

#### Patient consent statement

All pictures and investigations shown in this article are shown with the patients' consent. We require Authors to maintain patients' anonymity and to obtain consent to report investigations and pictures involving human subjects when anonymity may be compromised. The Journal follows the Guidelines of the Uniform Requirements for Manuscripts ([http://www.icmje.org/urm\\_full.pdf](http://www.icmje.org/urm_full.pdf)). The Foundation Years Journal requires in its Guidelines for Authors a statement from Authors that "the subject gave informed consent".

#### Animal & human rights

When reporting experiments on human subjects, the Foundation Years Journal requires authors to indicate whether the procedures followed were in accordance with the ethical standards of the responsible committee on human experimentation (institutional and national) and with the Helsinki Declaration of 1975, as revised in 2008.

## A PATIENT PRESENTS WITH ACUTE ABDOMINAL PAIN

A Oakes, C Patel, R Chakravartty, S Idriz

### Abstract

A patient presents with acute abdominal pain and after full work up an unusual cause is found.

### Case

A 79 year old female presented at the Emergency Department at 1905 with a one day history of severe abdominal pain that had initially eased but then worsened. It was a dull ache in the RIF and epigastrium, which was worse on moving, and at worst was 10/10.

She was nauseous, but had not vomited, had normal bowel opening, and had a reduced appetite since the pain began. She denied having any fevers. She also mentioned a recent LRTI for which she took steroids and amoxicillin and completed the course 2 days prior to admission.

### PMH

- COPD – SOB on walking up stairs
- Hypothyroid
- Self-catheterises for incomplete bladder emptying secondary to suspected detrusor failure. Recurrent UTI – normal cystoscopy in 2015.
- Previous *C.difficile* after treatment for arm cellulitis 2015 after which she had persistent loose stools - Colonoscopy in 2016 showed uncomplicated sigmoid diverticulosis.
- No previous abdominal surgery

### DH

- NKDA
- Levothyroxine 100mcg OD
- Omeprazole 10-20mg OD
- Sereflo (Fluticasone 125mcg/salmeterol 25mcg) 2 puff BD
- Seebri (glycopyrronium bromide 44mcg) inhaler once daily
- Imdapamide 1.5mg OD

### SH

- Non smoker, occasional alcohol
- Retired
- Lives with husband
- Normal ADLs

On examination her observations were: temperature 36.5°C, heart rate 99 bpm, blood pressure 150/98mmHg, respiratory rate 21 pm, saturations 98% on room air, GCS 15/15.

She looked in pain, had a tender epigastrium/central/RIF (which was the most tender area). Her abdomen was distended; she had sluggish bowel sounds and was Rovsing positive.

Consultant review was done at 1930 with a differential of diverticulitis or a perforated diverticulum. The team gave intravenous fluids, analgesia (paracetamol and oramorph), antiemetics (ondansetron and cyclizine), awaited the bloods to give antibiotics, organised a CT scan with further treatment based upon what was identified.

### Her initial investigations showed:

- Urine - trace blood and leukocytes.
- VBG - pH 7.45, BE 5.1, HCO3 28, Lac 0.9.
- Bloods - WCC 10.1, CRP 44, ALP 207, ALT 516, Bilirubin 30, the rest were normal

The CT was done and reported at 2059 with the findings: “a dilated loop of small bowel inferior to the liver with a “faeces in bowel sign” - such appearances are suggestive of slowed peristalsis/obstruction and therefore one of the differentials was internal hernia causing possible obstruction.

Another possibility was simply a collection. No free air or fluid.” Several images are included below.

## A PATIENT PRESENTS WITH ACUTE ABDOMINAL PAIN

A Oakes, C Patel, R Chakravartty, S Idriz

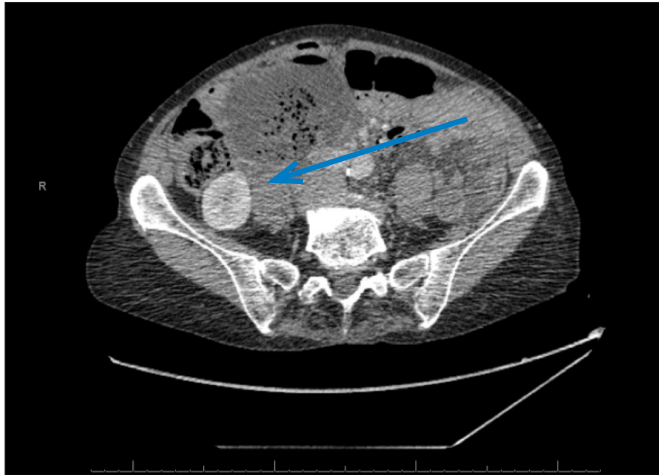


Figure 1: Axial image.

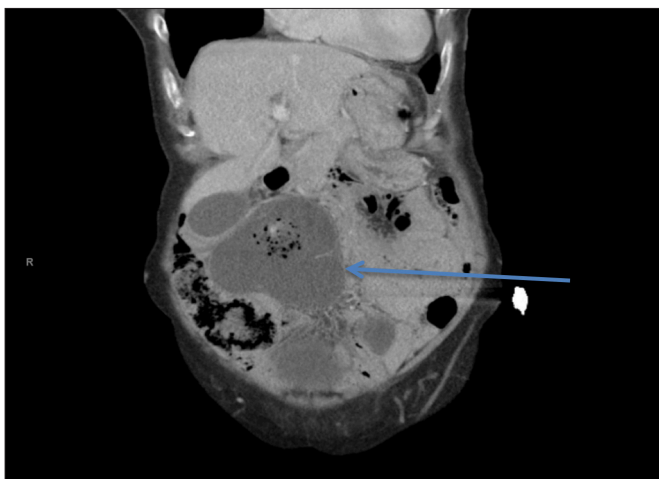


Figure 2: Coronal image.

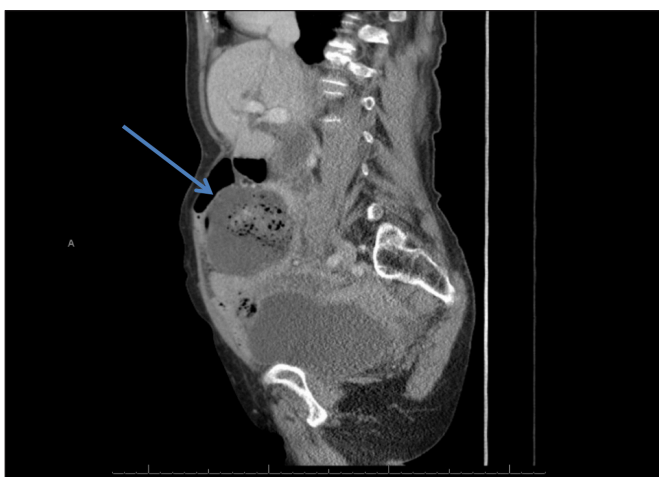

Figure 3: Sagittal image.

The patient was subsequently given intravenous co-amoxiclav 1.2g at approximately 2200, observed overnight and despite feeling better the next morning, she was still tender in the RIF, and although her abdomen was mildly distended she was not peritonitic.

Later that day she had a diagnostic laparotomy which found a large intraperitoneal mass seen extending from the gall bladder to RIF – a duodenal diverticulum, which was soft and hollow to palpate. Multiple loops of small bowel were slightly distended but otherwise normal. The caecum was distended with gas but there was no apparent mass.

Intra-operatively it was decided there was no benefit from further surgery and they closed with a plan to treat conservatively. She had the IV antibiotics changed to cefuroxime and metronidazole peri-operatively to treat diverticulitis which continued for 4 days and were then changed to oral co-amoxiclav 625mg.

She clinically improved and was discharged 6 days after admission with a plan for 6 more days of oral antibiotics and routine follow up with surgical team as an outpatient.

### Discussion

- The patient was clearly in significant discomfort and the presentation had a potentially wide variety of differentials, many of which carry significant morbidity and mortality. Typical concerning potential diagnosis of the acute abdomen include; diverticulitis, collection, perforation, bowel ischaemia/infarct, bowel obstruction (due to cancer, adhesions and hernia), biliary tract sepsis, pyelonephritis, aorta pathology, malignancy.

- To compound the issue was the fact that the patient is older – as we age there are a variety of physiological changes, especially to our immune system, meaning that patients can have atypical presentations or more normalised vital signs and blood results whilst still acutely unwell. It may not be until they decompensate that it is evident just how sick they are.

- The management of the patient appeared entirely appropriate – they had prompt IV antibiotics, analgesia, senior review and a CT. Conservative treatment was initiated after a judgement that urgent laparotomy was not warranted. After 'watchful waiting' a decision was made for a diagnostic laparotomy which revealed the cause of the patient's pain.

- Abdominal pain is a common presenting complaint to both general practise and the emergency department and it can take many years of experience to be able to safely triage those that require more immediate treatment. As in many areas of medicine it is often not the sickest patients that are hardest to manage, and particularly in younger patients it can be tricky to decide if a radiation exposure is warranted during the investigative process.

## A PATIENT PRESENTS WITH ACUTE ABDOMINAL PAIN

A Oakes, C Patel, R Chakravartty, S Idriz

### - Imaging options and reasoning for patients with abdominal pain include:

- CXR – to look for pneumoperitoneum or lower lobe pneumonia.
- AXR – pneumoperitoneum, bowel obstruction, colitis, hernia, volvulus, renal tract stones, psoas collection, AAA, gross malignancy or ascites can be identified.
- USS – useful for large collections, appendicitis, uterine or ovarian pathology, AAA, pancreatic/biliary tree/hepatic/renal tract pathology, malignancy or ascites can be identified.
- CT (with contrast if renal function permits) – the gold standard, commonly used to detect AAA, renal tract or GI pathology
- MRI – not used in the acute setting other than abscess secondary to discitis.
- If a patient requires a CT scan they should be reviewed by a senior colleague (registrar or consultant) as they are likely to have either something insidious or urgent, both of which require senior input.
- Pain and its control are huge topics that have vast volumes written on them. Early on in your training it is easiest to use simple questions and a decision tree (1,2,3,4) to aid you in your recognition and treatment of pain in the acute setting.

How severe is the pain (mild, moderate, severe), is the patient NBM or able to take pain control orally, are there any allergies or significant interactions/contraindications (e.g. NSAIDs in GI bleeding), should you use adjuncts e.g. antiemetics. Simple analgesia such as paracetamol (PO or IV) should be used in mild analgesia, combined with oral opioids +/- NSAIDs (if appropriate) in moderate analgesia, with IV opioid in severe pain.

### What to do if you are the lone foundation doctor reviewing a patient with acute abdominal pain:

- When and how to call the Registrar? – If you or the nursing staff recognise the patient is unwell or you are unsure. Use the bleep system or go via switch on mobile. If no success try areas such as theatre or surgical assessment.
- What my Registrar will want to know? – Patient demographics, where they are in the hospital, history of presenting complaint, relevant surgical/medical/drug history, allergies, last meal, vital signs, blood results, imaging done/planned.
- Red flags! – High early warning score (see local protocol), abnormal blood gas (ABG or VBG), significant pain, patient looks unwell or concern from nursing staff.

- How to make sure I am safe? – Involve all team members, take responsibility for a patient and make sure they are getting antibiotics/analgesia/urgent review/imaging, document what you have done.

- What are the first steps if the Registrar is not available? – In normal working hours if the registrar is unavailable and the patient is very unwell speak to the on call consultant. If it is non urgent speak to your SHO or one of the other registrar if they are available. Out of ours you should speak to the on call consultant.

- Prescribing – check for allergies, refer to local antibiotic guidelines for 'intra-abdominal sepsis', ensure patient gets appropriate analgesia.

### Test yourself

**1. What is the most appropriate pain relief in a 50 year old male who presents with sudden onset, 9/10 left loin to groin pain which comes in 'waves'. He is diaphoretic and has a heart rate of 110 bpm but otherwise well. He has no significant past medical history, takes only vitamin supplements and has no drug allergies.**

- a. Paracetamol IV.
- b. Morphine IV.
- c. NSAID PR + antiemetic.
- d. NSAID PR + Morphine IV + antiemetic.
- e. Paracetamol PO + Morphine IV + antiemetic.

**2. What imaging modality is most appropriate for an mildly overweight, but otherwise fit and well 23 year old male who presents with a 48 hour history of centralised abdominal pain which has localized in the right iliac fossa. His pain has slowly worsened and although his vital signs are within normal limits, his urine and blood results are mostly normal, his WCC is 12 and CRP 30.**

- a. CXR
- b. AXR
- c. Ultrasound abdomen
- d. No imaging required
- e. CT abdomen

## A PATIENT PRESENTS WITH ACUTE ABDOMINAL PAIN

A Oakes, C Patel, R Chakravartty, S Idriz

### Question 1

- The patient is in severe pain, meaning that strong opioid analgesia is indicated.
- Using analgesia in combination is often more effective due to the different mechanisms of action and more consistent therapeutic levels.
- In this instance the most likely differential diagnosis is renal colic for which NSAIDs (in this instance given PR) is highly effective.
- When giving strong opioids patients often feel nauseous and it is prudent to give an antiemetic as prophylaxis, preferably IV and prior to the opioid.
- Thus in this instance options 'd' or 'e' would be most appropriate with 'd' the best due to the NSAIDs being most effective in renal colic.

### Question 2

- The most likely diagnosis in this case is acute appendicitis.
- A scoring system such as the Alvarado or Appendicitis Inflammatory Response score (5,6) can be useful as a 'rule out' tool but should never replace a well taken history and clinical examination.
- Since the patient is young and we can be relatively confident about the diagnosis we would try to avoid CT. Ultrasound can be helpful but since the patient is overweight it is unlikely to add anything further and would simply delay treatment. An AXR also would likely add little information but unnecessarily expose the patient to radiation.
- In an otherwise fit young male it would be reasonable to investigate no further and proceed to a laparoscopy thus 'd' is the best answer although 'a' would be acceptable.

### Authors

#### Alastair Oakes

Radiology ST2  
Royal Surrey County Hospital  
Egerton Road  
Guildford  
GU2 7XX

#### Chandni Patel

Radiology ST2  
Royal Surrey County Hospital  
Egerton Road  
Guildford  
GU2 7XX  
chandni.patel4@nhs.net

#### Riddhika Chakravartty

Radiology ST2  
Guildford Road, Chertsey, KY16 OPZ  
riddhika.chakravartty@nhs.net

#### Sanjin Idriz

Radiology Consultant  
Royal Surrey County Hospital  
Egerton Road, Guildford, GU2 7XX  
sanjin.idriz@nhs.net

### Corresponding Author

#### Alastair Oakes

alastairoakes@hotmail.com

### References

1. Aneurin Bevan Health Board. 2012. Analgesic ladder for inpatient use.
2. Australian and New Zealand College of Anaesthetists and Faculty of Pain Medicine. 2010. Acute Pain Management: Scientific Evidence.
3. Royal College of Anaesthetists. 2018. Opioids and Acute Pain Management.
4. Morris, W., Goucke, R. 2016. Essential Pain Management Workshop.
5. <https://www.mdcalc.com/alvarado-score-acute-appendicitis>
6. <https://www.mdcalc.com/appendicitis-inflammatory-response-air-score>

Crockett, A. Pneumonia in the elderly: diagnosis and management. *Geriatric Medicine*. 2006, 36:49-52.

Kollar, D., McCartan D., Bourke, M., Cross, K., Dowdall, J. Predicting acute appendicitis? A comparison of the Alvarado score, the Appendicitis Inflammatory Response Score and clinical assessment. *World Journal of Surgery* 2015, 39(1):104-9.

Bryan, D., 2017. Abdominal Pain in Elderly Persons. <https://emedicine.medscape.com>

Spangler, R., Van Pham, T., Khoujah, D., Martinex, J. Abdominal emergencies in the geriatric patient. *International Journal of Emergency Medicine*, 2014, 7:43.

### Disclaimers

#### Conflict of interest

The Foundation Years Journal requires that authors disclose any potential conflict of interest that they may have. This is clearly stated in the Journal's published "Guidelines for Authors" ([https://www.123library.org/misc/FY\\_Guidelines\\_For\\_Authors.pdf](https://www.123library.org/misc/FY_Guidelines_For_Authors.pdf)). The Journal follows the Guidelines against Conflict of Interest published in the Uniform Requirements for Manuscripts Submitted to Biomedical Journals ([http://www.icmje.org/urm\\_full.pdf](http://www.icmje.org/urm_full.pdf)).

#### Financial statement

The authors of this article have not been paid. The Foundation Years Journal is financed by subscriptions and advertising. The Journal does not receive money from any other sources. The decision to accept or refuse this article for publication was free from financial considerations and was solely the responsibility of the Editorial Panel and Editor-in-Chief.

#### Patient consent statement

All pictures and investigations shown in this article are shown with the patients' consent. We require Authors to maintain patients' anonymity and to obtain consent to report investigations and pictures involving human subjects when anonymity may be compromised. The Journal follows the Guidelines of the Uniform Requirements for Manuscripts ([http://www.icmje.org/urm\\_full.pdf](http://www.icmje.org/urm_full.pdf)). The Foundation Years Journal requires in its Guidelines for Authors a statement from Authors that "the subject gave informed consent".

#### Animal & human rights

When reporting experiments on human subjects, the Foundation Years Journal requires authors to indicate whether the procedures followed were in accordance with the ethical standards of the responsible committee on human experimentation (institutional and national) and with the Helsinki Declaration of 1975, as revised in 2008.



## RADIOLOGY: A SNEAK PEEK INTO THE DARK SIDE TO THE OUTSIDE WORLD

S Ramachandraiah, C Peebles

### Abstract

This is a sincere attempt to give a taster of one of the most rewarding careers in medicine. Radiology department is usually "hidden away in the dark" and many as medical students or foundation doctors do not consider it to be an option while choosing future careers just because of lack of exposure.

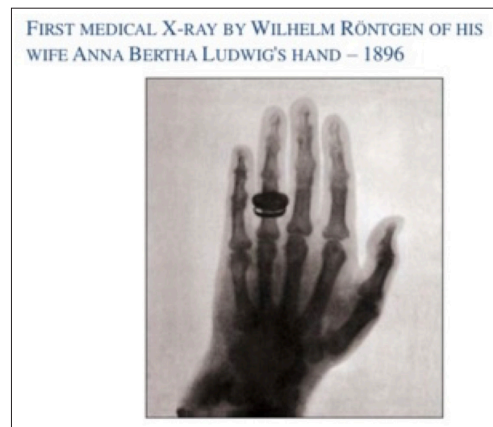
### History Of Radiology

- A great discovery of X-rays was made at the University of Wurzburg in 1895.
- Wilhelm Conrad Roentgen discovered X-rays.



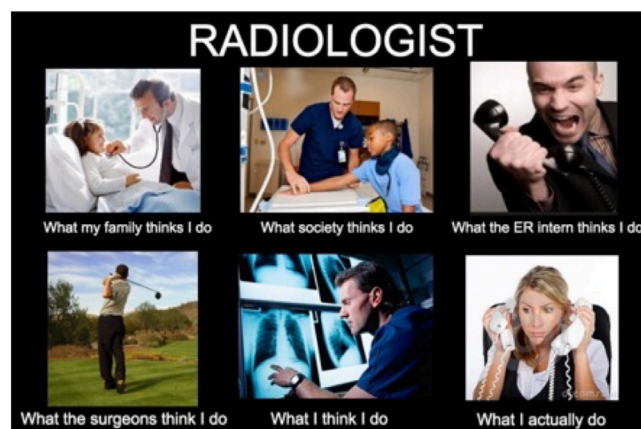
### Important Days in Radiology

- The day was **November 8 1895**, the day that Wilhelm Conrad Roentgen discovered the existence of x-rays in 1895, which is celebrated as The International Day of Radiology (IDoR) annually, as a day of action and awareness.
- It was first introduced in 2012, as a joint initiative, by the European Society of Radiology (ESR), the Radiological Society of North America (RSNA), and the American College of Radiology (ACR).
- On December 22, 1895, Roentgen asked his wife Anna Bertha if he could make a radiograph of her hand. On the photographic plate the bones of her hand and two rings can be seen distinctively. This picture became a historic document and 22 December, 1895 became the true birthday of radiology as a medical specialty.



### Practical points

- Radiologists are doctors (usually post FRCR/ MRCS/ MRCP or in training, post foundation years)
- Radiographers are professionals trained in exposure of imaging doses of radiation, they are not doctors



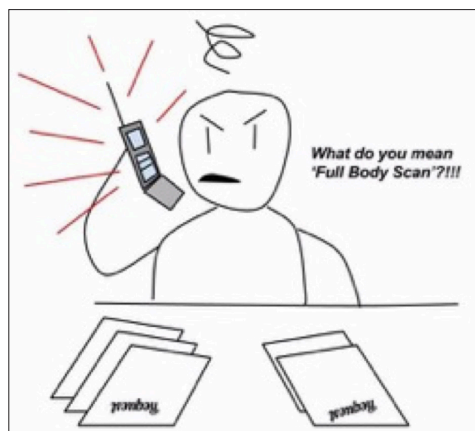- Imaging ( or other investigations) are requested not ordered.
- Imaging request cards are legal documents and as such must be filled out completely and truthfully

## RADIOLOGY: A SNEAK PEEK INTO THE DARK SIDE TO THE OUTSIDE WORLD

S Ramachandraiah, C Peebles

### How to approach a Radiologist

- Radiologists all used to be clinicians and have all in the dim and distant past been in the same position as you.
- Remember at the end of the day there is a patient we are trying to help.
- All you need to know is these basic things before requesting a radiological test.




- At the very least see the patient and know the basic history. There is no contraindication to physical examination
- Have the results of basic investigations to hand (including plain films)
- Ask a clinical question. There may be a better test than the one that you are asking for!
- If you don't know what question you are asking; ask your Registrar or Consultant to clarify

### How not to get a scan

- "I want to order a CTPA....."
- "I don't know why- my consultant asked me to get it"
- "I don't know they are not my patient" (They certainly don't belong to the Radiologist)
- Lie on the request card (potentially referable to the GMC)
- Interrupting Radiologist when mid report, hugely annoying- you don't walk into Theatre and disrupt the operation.
- Be rude to the radiographers, they control the speed of all lists and de facto whether a scan gets done or not.

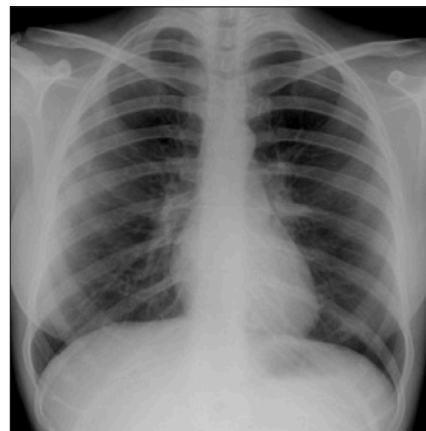
### Common Radiological Modalities – explained in simple terminology (non-exhaustive):

#### X-RAY PLAIN RADIOGRAPHY



X-Rays are passed through a part of the body to be imaged from a controlled source, while some xrays get absorbed some pass straight through the body which are then captured as a hard copy image or onto computer.

#### Plain radiograph – A 2D image of a 3D object



#### Advantage

*Quick, good initial assessment.*

*Less radiation when compared to CT*

#### Disadvantage

*Extensive overlap*

*Less spacial Resolution*

- **Portable radiograph:** If a patient is "too sick to leave the bed", radiographers can bring the portable machine to the ward.

## RADIOLOGY: A SNEAK PEEK INTO THE DARK SIDE TO THE OUTSIDE WORLD

S Ramachandraiah, C Peebles

### Advantage

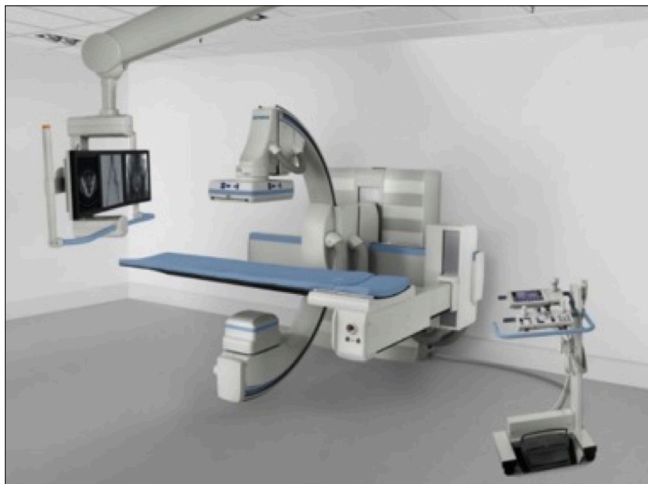Able to get imaging at patient's bedside.

### Disadvantage

Decreased quality due to unconventional projection  
Increased radiation risk to surrounding patients and staff

- **Stress radiograph** : Apply stress ( eg Make patient stand, force or extra weights to carry) on specific organs eg: joints. To mimic normal physiological stress to review what changes it brings as opposed to resting radiographs.

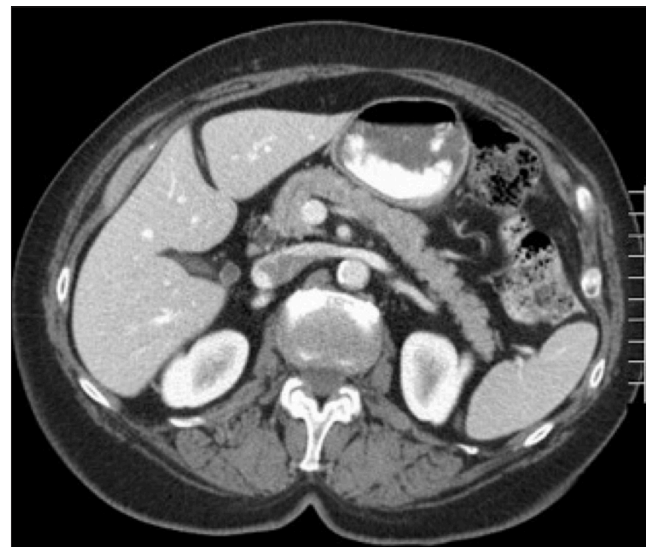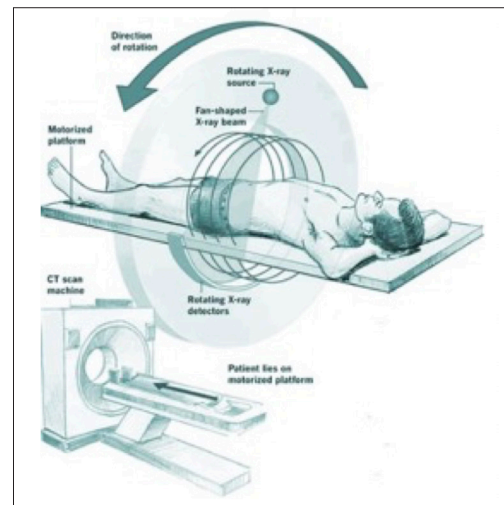
### • FLUOROSCOPY



When the X-ray beam is used with a video screen, to allow visualisation of the movement of a body part or of an instrument or contrast through the body in real time. The following are the common uses:

- *Angiography of the leg, heart and cerebral vessels*
- *Orthopaedic surgery*
- *Blood flow studies*
- *Catheter insertion*
- *Upper GI studies*
- *Urological studies*
- *Implantation of pacemakers*

### CT SCAN COMPUTERISED TOMOGRAPHY



- Passing a thin x-ray beam through the body of the patient in the axial plane, as the x-ray tube moves in a continuous arc around the patient.
- The opposite side of the x-ray are electronic detectors. These detectors convert the exit beam into electronic signal.
- The signals are sent to the computer which calculates the x-ray absorption values and arranges the images.

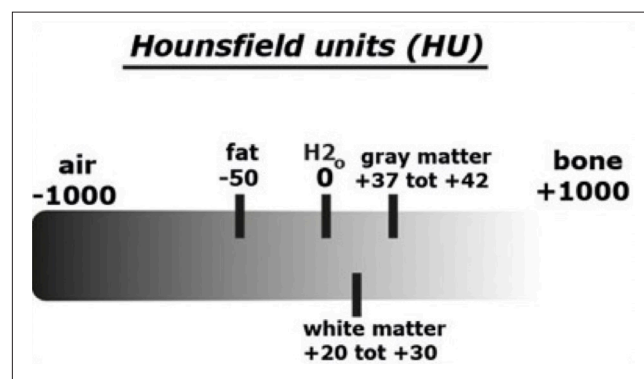
**There are 5 main radio densities mainly applicable in CT, also can be used in plain radiographs. In CT it is much more clearer due to good contrast resolution and is formally called the CT number and was initially called Hounsfield Unit.**

## RADIOLOGY: A SNEAK PEEK INTO THE DARK SIDE TO THE OUTSIDE WORLD

S Ramachandraiah, C Peebles

- Hounsfield units, created by and named after Sir Godfrey Hounsfield, are obtained from a linear transformation of the measured attenuation coefficients 1. This transformation (figure 1) is based on the arbitrary definitions of air and water:

- radiodensity of distilled water at standard temperature and pressure (STP) = 0 HU
- radiodensity of air at STP = -1000 HU



### What is useful to know about CT as a clinician:

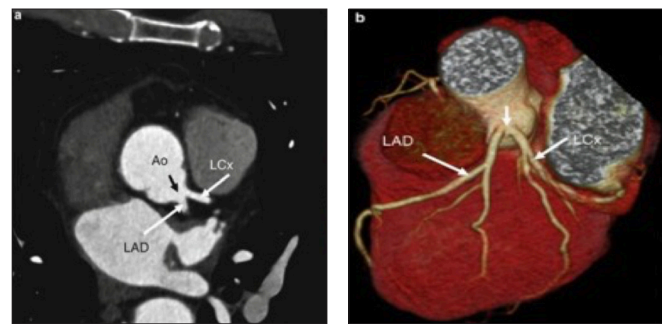
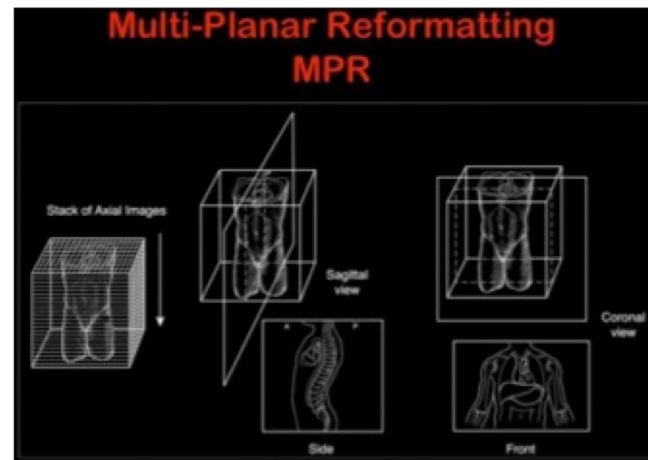
- Is the indication right and you definitely need the test. Ask and confirm the indications with your seniors before requesting the scan.
- CT is a test that involves radiation (Please rule out pregnancy where applicable, inform the patient)
- If unsure of the underlying pathology, please make sure you mention the differential diagnosis – this helps radiologists make sure they perform the right protocol which is very important to be able to answer the clinical question.

**Eg:** If the question is related to pancreas, we would perform triple phase CT without oral contrast, which is a lot more radiation than just a single phase porto-venous scan we would perform if the question was ?diverticulitis or appendicitis.

- Please enquire if contrast is needed – if yes, ask what cannulas we need, check renal function. Read your trust policy for contrast induced nephropathy (usually simple rehydration prior to scan will suffice but you need to be aware of availability for escalation of renal care if you encounter contrast induced nephropathy although unlikely – reference: Jeremiah S. Hinson, MD, PhD et al, Risk of Acute Kidney Injury After Intravenous Contrast Media Administration, published 2016 by the American College of Emergency Physicians. <http://dx.doi.org/10.1016/j.annemergmed.2016.11.021>

- If in doubt, discuss with a radiologist.

- Almost all CT scans are acquired in axial planes which can be viewed in multiplanar reformats (MPR)- sagittal, coronal, 3D and others.



### CT Angiogram

- Scanning when the IV contrast bolus reached its peak in the vascular structures being studied (either arterial or venous)
- When compared to conventional angiograms this is quicker and gives same information. However the down side is that it uses radiation and IV contrast material and an immediate treatment cannot be done like clot retraction or stent or coil placement.

### MRI: Magnetic Resonance Imaging

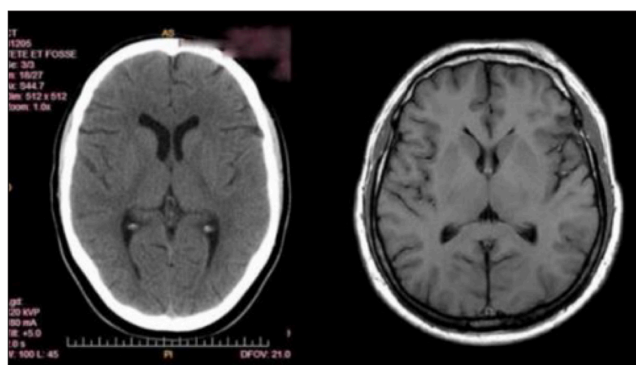
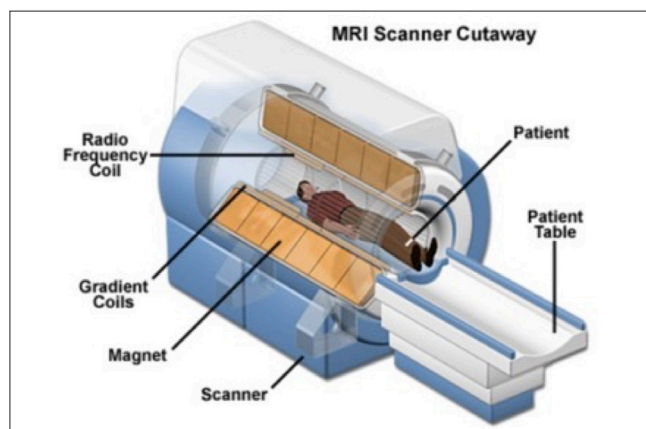
- The human body is mostly water. Water molecules (H<sub>2</sub>O) contain hydrogen nuclei (protons), which become aligned in a magnetic field. An MRI scanner applies a very strong magnetic field (0.3 to 3 Tesla in clinical practise), which aligns the proton “spins.”

- The scanner also produces a radio frequency current that creates a varying magnetic field. The protons absorb the energy from the magnetic field and flip their spins. When the field is turned off, the protons gradually return to their normal spin, a process called precession. The return process produces a radio signal that can be measured by receivers in the scanner and made into an image.



## RADIOLOGY: A SNEAK PEEK INTO THE DARK SIDE TO THE OUTSIDE WORLD

S Ramachandraiah, C Peebles



The above shows the difference in soft tissue details MR (your right side image) can provide when compared to CT. These are axial sections of brain.

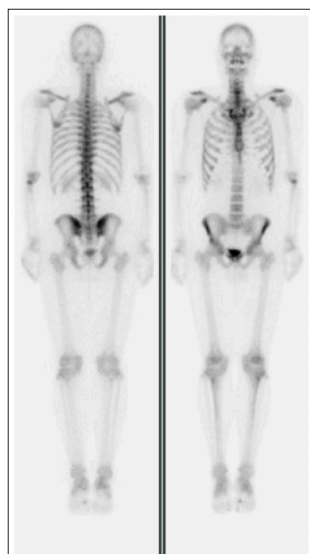
CT Scan versus MRI comparison		
	CT Scan	MRI
<b>Radiation exposure</b>	The effective radiation dose from CT ranges from 2 to 10 mSv, which is about the same as the average person receives from background radiation in 3 to 5 years. Usually, CT is not recommended for pregnant women or children unless absolutely necessary.	None. MRI machines do not emit ionizing radiation.
<b>Time taken for complete scan</b>	Usually completed within 5 minutes. Actual scan time usually less than 30 seconds. Therefore, CT is less sensitive to patient movement than MRI.	Depending on what the MRI is looking for, and where it is needing to look, the scan may be quick (finished in 10-15 minutes) or may take a long time (2 hours).
<b>Effects on the body</b>	CT can pose the risk of irradiation. Painless, noninvasive.	No biological hazards have been reported with the use of MRI.
<b>Application</b>	Suited for bone injuries, Lung and Chest imaging, cancer detection. Widely used on Emergency Room patients.	Suited for Soft tissue evaluation, e.g., ligament and tendon injury, spinal cord injury, brain tumors, etc.
<b>Details of bony structures</b>	Provides good details about bony structures	Less detailed compared to X-ray
<b>Details of soft tissues</b>	A major advantage of CT is that it is able to image bone, soft tissue and blood vessels all at the same time.	Provides much more soft tissue detail than a <a href="#">CT scan</a> .
<b>Principle</b>	X-ray attenuation is detected by detector & DAS system, followed by math. model (back projection model) to calculate the value of pixelism that becomes a image.	Body tissues that contain hydrogen atoms (e.g. in water) are made to emit a radio signal which are detected by the scanner. Search for "magnetic resonance" for physics details.
<b>Image specifics</b>	Good soft tissue differentiation especially with intravenous contrast. Higher imaging resolution and less motion artifact due to fast imaging speed.	Demonstrates subtle differences between different kinds of soft tissues.
<b>Intravenous Contrast Agent</b>	Non-ionic iodinated agents covalently bind the iodine and have fewer side effects. Allergic reaction is rare but more common than MRI contrast. Risk of contrast induced nephropathy (especially in renal insufficiency (GFR<60), diabetes & dehydration).	Very rare allergic reaction. Risk of reaction in those who have or have a history of kidney or liver disorders.
<b>Comfort level for patient</b>	Seldom creates claustrophobia	Anxiety, especially anxiety caused by claustrophobia, is common, as is tiredness or annoyance over having to stay still on a hard table for a long period of time.
<b>Limitation for Scanning patients</b>	Patients with metal implants can get CT scan. A person who is very large (e.g. over 450 lb) may not fit into the opening of a conventional CT scanner or may be over the weight limit for the moving table.	Patients with Cardiac Pacemakers, tattoos and metal implants are contraindicated due to possible injury to patient or image distortion (artifact). Patient over 350 lb may be over table's weight limit. Any ferromagnetic object may cause trauma/burn.

### Nuclear Medicine

- Small amounts of radioactive materials called radiotracers are combined with chemical compounds to make radiopharmaceuticals that are typically injected into the bloodstream, inhaled or swallowed. The radiotracer travels through the area being examined and gives off energy in the form of gamma rays which are detected by a special camera and a computer to create images
- Nuclear medicine has been the largest contributor to physiological imaging.
- The radiopharmaceuticals used in diagnostic nuclear medicine tend to emit gamma rays since these can be detected from outside the patient. Ionising radiation can be hazardous and because of this its use in medicine is regulated in law (IRR, 1999, IRMER, 2000). However the radiation dose that a patient receives from a diagnostic nuclear medicine procedure is very small and is about the same as the unavoidable amount of radiation that everyone receives from natural background radiation each year.

#### Few examples of different NM scans

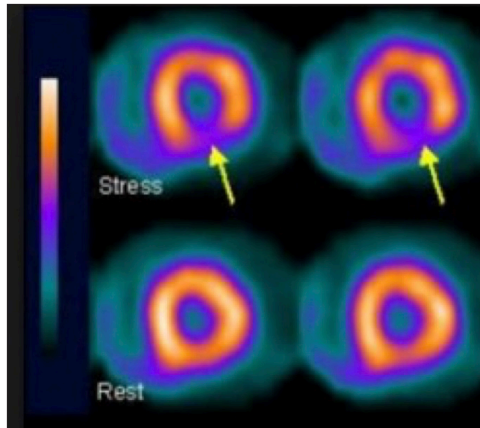
- *Bone scan*



## RADIOLOGY: A SNEAK PEEK INTO THE DARK SIDE TO THE OUTSIDE WORLD

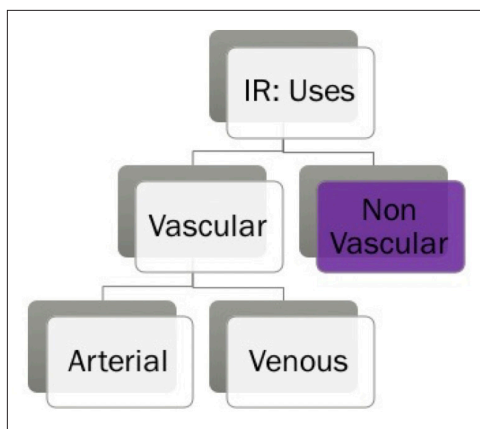
S Ramachandraiah, C Peebles

- PET
- Myocardial perfusion scan



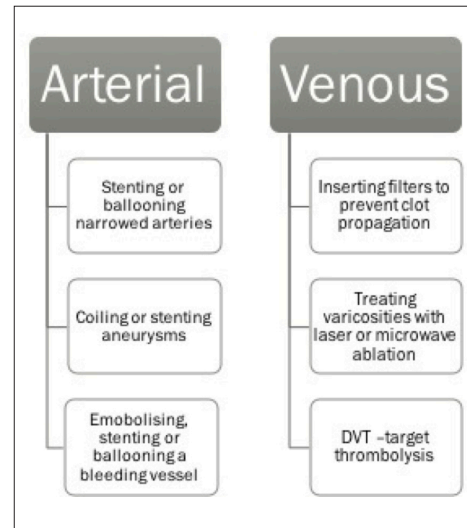
### INTERVENTIONAL RADIOLOGY

- The concept behind interventional radiology is to diagnose and treat patients using the least invasive techniques currently available in order to minimize risk to the patient and improve health outcomes. These procedures have reduced risks, shorter hospital stays, lower costs, greater comfort, quicker convalescence and return to work.
- Rely on the use radiological image guidance (X-ray fluoroscopy, ultrasound, computed tomography [CT] or magnetic resonance imaging [MRI]) to precisely target therapy.



#### Non Vascular

- to treat the tumour / cancer (tumour ablation, embolization)
- to relieve the effects of the cancer on other systems e.g. blockage of the gullet (oesophagus), bowel, kidney (nephrostomy) or liver (biliary drainage)
- To drain collections of fluid or pus in the chest or abdomen
- To place feeding tubes (gastrostomy, jejunostomy)
- To treat collapsed spinal bones (vertebroplasty)



**Others:** Arterial/ venous line insertions, catheter and drain insertions eg: nephrostomy.

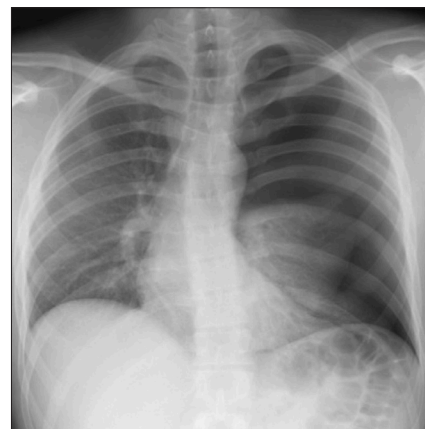
### Must see/life or limb threatening findings ( non exhaustive)

It is beyond the scope of this article to provide more examples and to explain each examples in detail.

I have not touched on - lines and tubes on plain radiographs, which is again very important to be familiar with on a day to day basis on the wards but it is impossible to cover everything.

I have provided few online resources which are very useful for understanding basics.

#### Tension pneumothorax

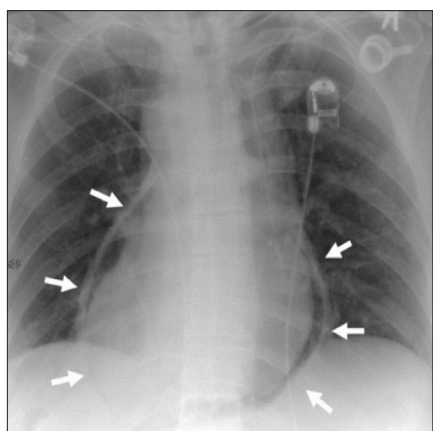




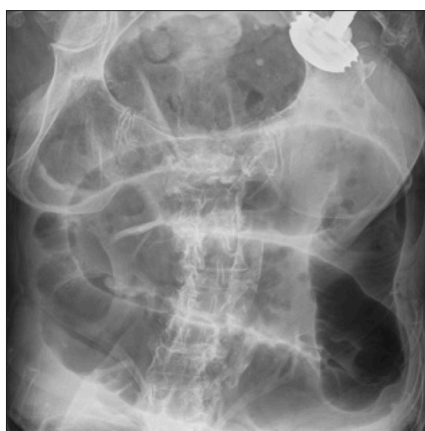# RADIOLOGY: A SNEAK PEEK INTO THE DARK SIDE TO THE OUTSIDE WORLD

S Ramachandraiah, C Peebles

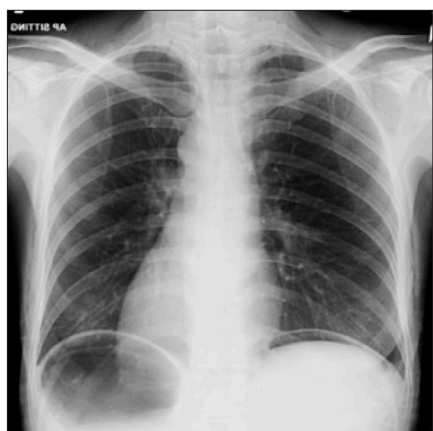**Pneumopericardium**



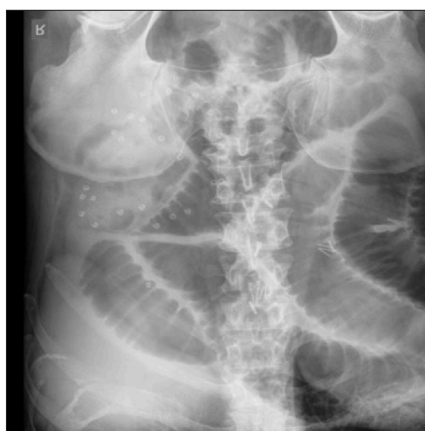**Large bowel obstruction**



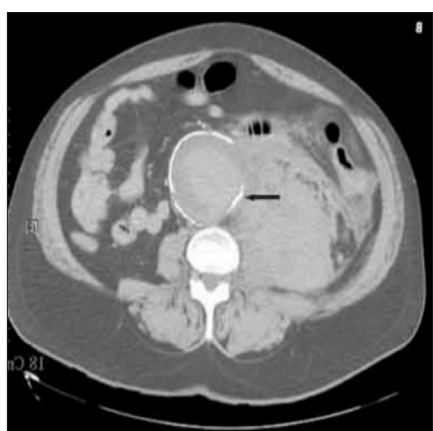
**Pneumoperitoneum**



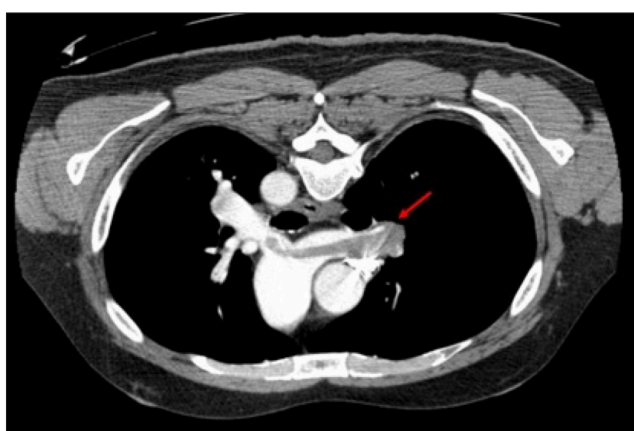**Small bowel obstruction**



**Abdominal aortic aneurysm rupture on CT**



**Pulmonary embolism**



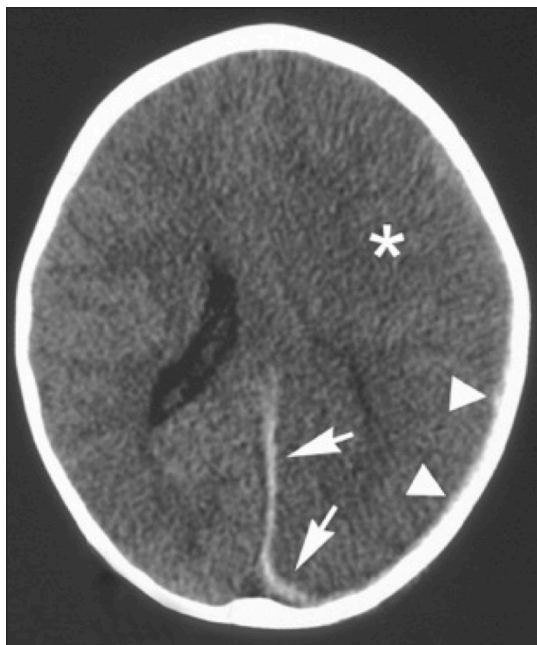
## RADIOLOGY: A SNEAK PEEK INTO THE DARK SIDE TO THE OUTSIDE WORLD

S Ramachandraiah, C Peebles

### Non Accidental Injuries

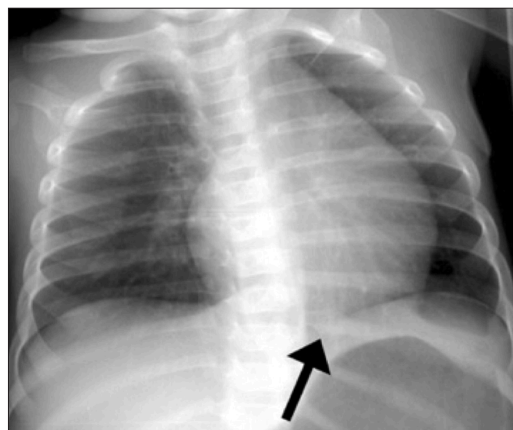
If you happened be the first person to suspect a non accidental injury in a child, you should be aware at least of few of the classic radiological findings,

- Multiple fractures of different age
- Posterior rib fracture
- Fracture of scapula or sternum
- Metaphyseal fracture
- Interhemispheric extradural hemorrhage
- Skull fractures especially involving multiple bones, crossing sutures or diastatic sutures



Axial unenhanced CT scan: Diffuse left hemispheric edema(\*), sulcal and left lateral ventricular effacement.

High-attenuation blood in the posterior interhemispheric fissure, extending to the left of the superior sagittal sinus (arrows) and along the left convexity (arrowheads).



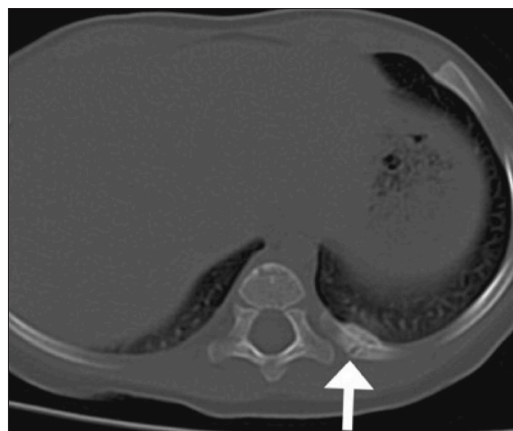
Chest radiograph and Bone windows on an axial CT across lower chest showing - healing posterior rib fracture in a 2year old.

### Further Reading

- *Making the Best Use of Clinical Radiology Services*, Royal College of Radiologists
- *ABC of Emergency Radiology*, Otto Chan, 2nd Edition, BMJ, 2007
- *Chest XRay/Abdominal XRays Made Easy* Churchill Livingstone
- *Felson's Principles of Chest Roentgenology* Lawrence Goodman 3rd Edition, Saunders, 2007

### Easy and free online resources for Radiology

- *Radiopaedia*
- *Learning radiology*
- *Radiology Assistant*
- *Don't forget your own Radiologist*



## RADIOLOGY: A SNEAK PEEK INTO THE DARK SIDE TO THE OUTSIDE WORLD

S Ramachandraiah, C Peebles



### MCQs

#### 1. Which of these radiology modalities DO NOT expose patient to radiation?

- a. CT right hip
- b. Barium swallow study (fluoroscopy)
- c. Whole body PET CT
- d. Brain MR
- e. Left foot radiograph

#### 2. Two important checks before requesting CT

- a. ESR
- b. eGFR
- c. CRP
- d. Beta HCG (in child bearing aged females)
- e. CA 125

#### 3. A chest radiograph shows LEFT sided white out with tracheal deviation to LEFT the possible explanation are all of these EXCEPT

- a. Left lung collapse
- b. Left pneumonectomy
- c. Left sided pleural effusion
- d. Foreign body obstructing left main bronchus
- e. ET tube- inappropriately positioned

#### 4. All of these are relative contraindications for gadolinium enhanced MR except

- a. Metallic foreign body within the eye
- b. Non compatible cardiac pacemaker
- c. Paediatric patients
- d. Biliary stents – 1-week post op
- e. Coronary stents

#### 5. Nice guidelines to obtain CT brain in adults with head injury include these except

- a. Panda eye
- b. One episode of vomiting after the injury
- c. Focal neurological deficit
- d. GCS <13
- e. Post traumatic seizure

## RADIOLOGY: A SNEAK PEEK INTO THE DARK SIDE TO THE OUTSIDE WORLD

S Ramachandraiah, C Peebles

### Answers

#### 1. d.

*MR does not use X-rays or radioactive material and thus no radiation risk.*

#### 2. b and d.

*Contrast induced nephropathy and radiation dose to foetus are the concerns.*

#### 3. c.

*Pleural effusion doesnot cause volume loss but the opposite.*

#### 4. e.

*Coronary stents are usually safe.*

#### 5. b

*(NICE guideline says >1 episodes of vomiting and in children it is more than 3 episodes )*

### Authors

#### Dr Sowkhya Ramachandraiah

Radiology Registrar, Wessex Deanery,  
Southampton General Hospital,  
Tremona Road, Southampton, SO16 6YD

#### Dr Charles Peebles

Consultant Radiologist  
University Hospitals Southampton

### Corresposnding Author

#### Dr Sowkhya Ramachandraiah

Sowkhya.Ramachandraiah@uhs.nhs.uk

### References

1. Radiology in a Trench Coat. Military Radiology on the Western Front during the Great War. Academia Press, Ghent. 2013. ISBN: 9-789038-219394.
2. Lee S, Crean M, et al. [http://www.bshr.org.uk/The\\_Story\\_of\\_Radiology\\_Volume\\_2\\_LR.pdf](http://www.bshr.org.uk/The_Story_of_Radiology_Volume_2_LR.pdf) Published 2013 by ESR in cooperation with IRSHAD – The International Society for the History of Radiology Deutsches Roentgen Museum.
3. Robert F. Dondelinger, et al. [https://www.internationaldayofradiology.com/app/uploads/2017/11/Help\\_ER-Book\\_IDOR2017.pdf](https://www.internationaldayofradiology.com/app/uploads/2017/11/Help_ER-Book_IDOR2017.pdf) Published by ESR, November 2017
4. Radiopaedia.org
5. Learningradiology.com
6. RCR and RCPCH reference articles
  - <https://www.rcr.ac.uk/publication/radiological-investigation-suspected-physical-abuse-children>
  - [https://www.rcpch.ac.uk/system/files/protected/news/StandardsforRadiologicalInvestigationsD\[1\].pdf](https://www.rcpch.ac.uk/system/files/protected/news/StandardsforRadiologicalInvestigationsD[1].pdf)

### Disclaimers

#### Conflict of interest

The Foundation Years Journal requires that authors disclose any potential conflict of interest that they may have. This is clearly stated in the Journal's published "Guidelines for Authors" ([https://www.123library.org/misc/FYJ\\_Guidelines\\_For\\_Authors.pdf](https://www.123library.org/misc/FYJ_Guidelines_For_Authors.pdf)). The Journal follows the Guidelines against Conflict of Interest published in the Uniform Requirements for Manuscripts Submitted to Biomedical Journals ([http://www.icmje.org/urm\\_full.pdf](http://www.icmje.org/urm_full.pdf)).

#### Financial statement

The authors of this article have not been paid. The Foundation Years Journal is financed by subscriptions and advertising. The Journal does not receive money from any other sources. The decision to accept or refuse this article for publication was free from financial considerations and was solely the responsibility of the Editorial Panel and Editor-in-Chief.

#### Patient consent statement

All pictures and investigations shown in this article are shown with the patients' consent. We require Authors to maintain patients' anonymity and to obtain consent to report investigations and pictures involving human subjects when anonymity may be compromised. The Journal follows the Guidelines of the Uniform Requirements for Manuscripts ([http://www.icmje.org/urm\\_full.pdf](http://www.icmje.org/urm_full.pdf)). The Foundation Years Journal requires in its Guidelines for Authors a statement from Authors that "the subject gave informed consent".

#### Animal & human rights

When reporting experiments on human subjects, the Foundation Years Journal requires authors to indicate whether the procedures followed were in accordance with the ethical standards of the responsible committee on human experimentation (institutional and national) and with the Helsinki Declaration of 1975, as revised in 2008.

## IMAGING A PATIENT WITH ACUTE BREATHLESSNESS

R Chakravartty, A Oakes, A Antonello, C Patel, V Prakash

### Abstract

This case study looks at the imaging of an adult patient presenting with acute shortness of breath. Clinical history and examination findings can focus on a differential diagnosis which then helps select an appropriate imaging modality. Factors affecting CT pulmonary angiography imaging are discussed with practical pointers to try avoid inappropriate referrals and reduce radiation burden for the patient.

### Case

A 47 year old man presented to the Accident and Emergency Department, complaining of shortness of breath, which began 24 hours ago and had steady increased over the last 6 hours, limiting his ability to sleep. He was presently confined to a chair and felt most comfortable in the upright position. He has no previous cardiac or respiratory history and has been fit and well.

He denied history of fever, cough, sneezing or any other upper respiratory symptoms but felt 'off colour' for the last few days. Of note, he suffered a left ankle fracture 4 weeks ago while playing football and has had his foot in a cast since the incident. He is a non smoker and has no known allergies.

On examination, his pulse was 100 beats per minute with a blood pressure of 136/88mm Hg and a respiratory rate of 30/min. His oxygen saturation was 95%, which improved to 98% with oxygen through nasal prongs. The jugular venous pressure was not raised. There was a marked wheeze during speech. Auscultation over the chest revealed rhonchi bilaterally, more marked in the bases posteriorly. His left ankle was still encased in the plaster cast. No significant findings on the rest of the examination.

Following review by the Emergency team, the patient was continued on oxygen with the addition of salbutamol nebulisation. Blood results were normal except for a white blood cell count of  $4.3 \times 10^9/L$  and a CRP of 27 mg/dl. An ECG tracing was unremarkable and Troponin markers were negative. A chest radiograph was requested to look for a respiratory cause.

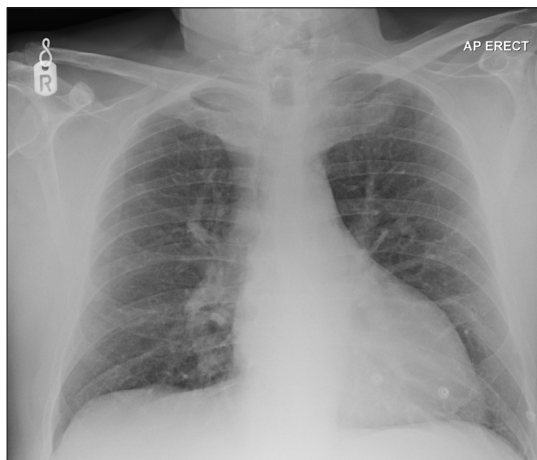


Figure 1: Chest Radiograph

Please take a minute to review the chest radiograph before proceeding. A systematic approach to a radiograph is useful especially during a busy A&E shift.

This AP chest radiograph is well centred with good inspiratory effort. The trachea is central with no focal air space opacification in either lung. Both costophrenic angles are preserved suggesting no pleural effusions. Despite the AP projection, the cardiac size appears normal and the mediastinal shadow is unremarkable. No hilar shadows are seen to suggest enlarged lymph nodes. The right hemi diaphragm is slightly raised as compared to the left, in keeping with the normal anatomy of the liver. There is no free air under either hemi diaphragm. No rib fractures seen.

In view of the normal findings on the chest radiograph, consolidation due to infection (pneumonia), pneumothorax and pleural effusions were ruled off the list of differential diagnosis. The differentials now being considered included bronchial based condition, possibly bronchitis, bronchiolitis or asthma. However given the recent ankle fracture and limited mobilisation, a Wells Score was calculated and found to be 4.

D Dimer levels were  $>1000$ . Given this, the team felt that a pulmonary embolism was within the differential. The iRefer interface, designed by the Royal College of Radiologists, suggested that a CT Pulmonary Angiogram (CTPA) was the best imaging modality to assess for this possibility in a young male.

The imaging request was accepted and the patient was called to the radiology department within an hour for his scan. No pre preparation was required though the radiographer checked the recent blood results to ensure that renal function was adequate for the administration of contrast. Intravenous access through a cannula was secured.

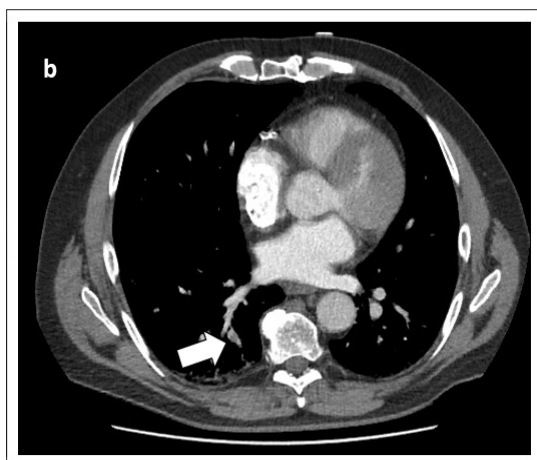
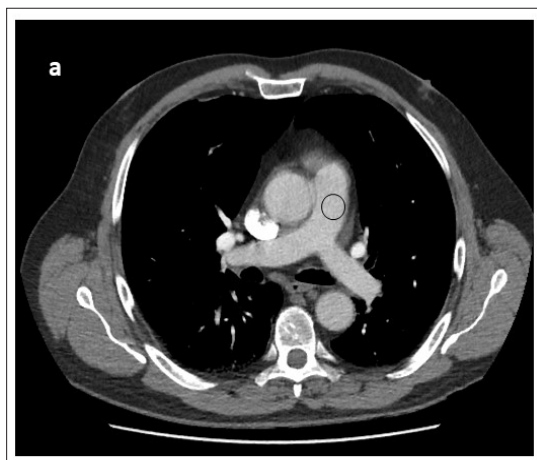
A CTPA study involves the injection of iodinated contrast through peripheral intravenous access. It travels through the arm veins, into the superior vena cava and the right side of the heart before entering the pulmonary arterial vasculature. Scanning is triggered when the contrast is felt to have opacified the pulmonary arterial tree, the chest being imaged from the neck to the upper abdomen.

The radiographer reviewing the initial images noticed that the main pulmonary artery did not look as bright as it should have and flagged this to the consultant radiologist.



## IMAGING A PATIENT WITH ACUTE BREATHLESSNESS

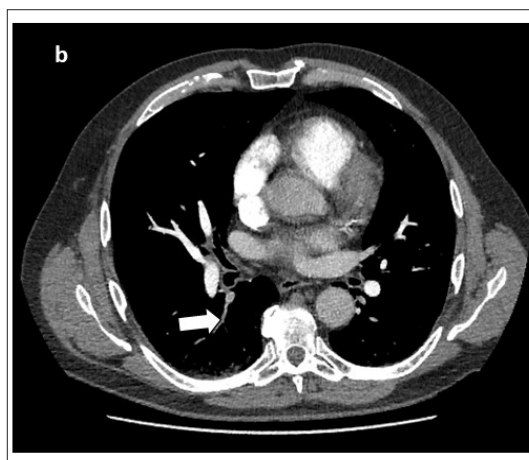
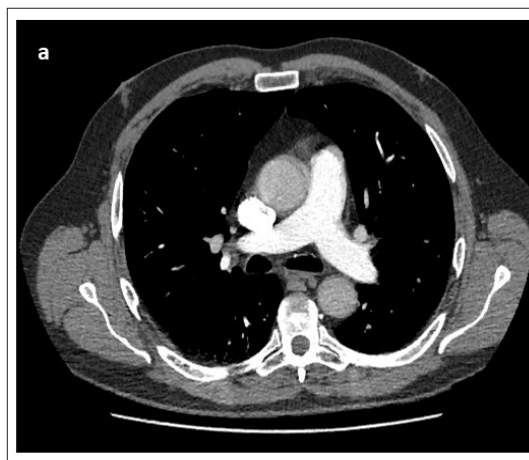
R Chakravartty, A Oakes, A Antonello, C Patel, V Prakash



**Figure 2: Initial attempt at CTPA imaging. Figure 2a reveals inadequate contrast in the main pulmonary artery with a region of interest (circle) showing a mean of 113HU. Figure 2b shows a possible filling defect (arrow) in one of the segmental branches in the right lower lobe.**

A region of interest placed over the main pulmonary artery (Figure 2A) gave a mean 113 Hounsfield Units (HU), well below the expected value of 220 HU. An initial glance through the images suggested a possible filling defect in one of the segmental branches in the right lower lobe however the level of confidence to call a pulmonary embolism was low given the poor arterial opacification. A decision to repeat the study was taken.

The intravenous access was re-checked prior to the administering a second bolus of contrast. This was found to be a small bore cannula which had been displaced, possibly by the pressure from the contrast injector. The new larger bore cannula was re sited and the imaging was re-acquired.



**Figure 3: Repeat CTPA imaging. Figure 3a shows adequate opacification of the pulmonary arterial tree. Figure 3b shows a filling defect (arrow) in the right lower lobe segmental branch.**

The repeat imaging depicted the main pulmonary artery in white (Figure 3a). A region of interest showed a mean of 250HU confirming adequate opacification. The filling defect in the right lower lobe was better visualised with the effect of better contrast and the diagnosis of a pulmonary embolism could be confidently made. There were no features to suggest right heart strain. There were no other significant findings.

The Emergency Department team were informed of these findings, who then relayed the findings to the medical on call team who took over the patient's care as an inpatient. The patient was treated with Daltaparin and his symptoms gradually resolved over the next 48 hours. A colour Doppler of the lower limbs did not show deep vein thrombosis. He was discharged with advice to follow up in a respiratory outpatient clinic.



## IMAGING A PATIENT WITH ACUTE BREATHLESSNESS

R Chakravartty, A Oakes, A Antonello, C Patel, V Prakash

### Discussion

CTPAs are one of the commonest referrals from A&Es often requested to rule out a pulmonary embolism. While requesting this imaging, it is important to establish a pre-test likelihood for pulmonary embolism. This is based on a combination of history, presence of precipitating factors (including known malignancy, haemophilia and a period of immobilisation) along with an absence of findings on the chest radiograph. The Wells score is a clinical tool which has been used with a varying degree of success to predict the likelihood of embolism occurrence.

A score of over 4 would certainly raise concern and warrant imaging confirmation. Another test result that a radiologist would ask for in order to justify the radiation dose is the D dimer. While this is often raised when pulmonary emboli are present, the D dimer is a nonspecific test which could be elevated in many inflammatory, infective or malignant conditions.

A low pre-test probability may suggest alternative diagnosis on the list of differentials, for example while investigating a patient with acute shortness of breath, a suspected cardiac pathology would make an echocardiogram a more appropriate investigation while an HRCT would be preferred for emphysema and chronic obstructive pulmonary disease. Hence tailoring the imaging request to reflect clinical suspicions is more likely to result in the request being justified for imaging and a useful result which adds value to the clinical decision making process.

When putting in a CTPA request, a few points should be kept in mind. CT Scanning requires the patient to lie either supine or prone on the imaging table for albeit a short duration of time usually less than five minutes. This may be difficult for very breathless patient and it would be preferable to ease breathing with nebulisers or inhalers prior to attempting the scan. Adequate renal function is important as iodinated contrast can be nephrotoxic.

It is important to document renal function prior to administering contrast and the radiographer may ask for a repeat Creatinine level, if the result available on the hospital system is a few years old or borderline. The last tip is to secure a large bore intravenous cannula, preferably a pink 20G or a green 18G cannula. Blue 22G cannulas may be used in extreme circumstances, particularly in patients with malignancies who have very few large veins available. Sorting these out in advance translates into a smoother imaging journey for both patient and the radiographer and will go a long way in helping avoid irate bleeps.

There are a number of reasons why a CTPA may be non-diagnostic, these may include some technical errors like triggering the scan too early or too late. In this case, the initial scan was non-diagnostic due to tracer extravasation. A CTPA can deliver up to 7mSv worth of radiation, equivalent to approximately 2 years' worth of background radiation per exposure.

Repeating the scan can be justified in the presence of a high pre-test probability but it does mean doubling the radiation dose to the patient. The concept with radiation is ALARA (as low as reasonably achievable) and members of radiology teams will strive to achieve this. Hence correctly siting an appropriate cannula can make a difference to the patient's radiation exposure.

Imaging remains the gold standard to prove a diagnosis of pulmonary embolism. But performing high quality and clinically useful imaging, needs input from the referring team, particularly complete clinical details and a specific clinical question. Even the junior most members of clinical teams have a role to play in making this happen.

### Test yourself

#### 1. The following criteria would justify a CTPA imaging request.

- A D dimer of 400 units
- A D dimer of 400 units and a Wells Score of 2
- A Wells Score of 5
- A D dimer of >1000 and a Wells Score of >4
- None of the above

#### 2. The following imaging modalities can be used to diagnose a pulmonary thromboembolism.

- Chest radiograph
- CT Pulmonary Angiogram
- VQ Scan
- MRI Thorax
- Chest ultrasound

#### 3. When informed about a positive CTPA result, the next step would be:

- Wait for the ward round to discuss the treatment plan
- Stop the prophylactic dose of Daltaparin and inform the medical team
- Check for contraindications to thrombolysis treatment and discuss therapeutic options with the medical registrar
- Discuss the possibility of thrombectomy with the interventional radiologist
- Consider whole body imaging to look for a neoplasm as a cause for the emboli

## IMAGING A PATIENT WITH ACUTE BREATHLESSNESS

R Chakravartty, A Oakes, A Antonello, C Patel, V Prakash

### Answers

#### 1. Answer: c and d.

The Wells Score is an adjunct tool to the clinical examination of a patient and can be useful for a pre test probability of pulmonary embolism. Software calculators are available for this (<https://www.mdcalc.com/wells-criteria-pulmonary-embolism>).

Using the two tier approach, a Wells Score of >4 would justify CTPA imaging. If the Wells score is between 0-4, the decision is made based on the D-dimer results. A negative D-dimer (<500 units) would suggest no need for further imaging. A positive D-dimer, despite the low sensitivity of the test, would justify CTPA imaging to rule out a pulmonary embolism.

#### 2. Answer: b and c

CTPAs are most commonly requested to rule out pulmonary embolism. Their advantage lies in the depiction of other causes of breathlessness, including cardiac, respiratory and mediastinal pathologies, particularly when no pulmonary embolism is seen. However VQ Scans are another way of imaging pulmonary embolism, relying on a perfusion ventilation mismatch.

These are performed particularly when patients have had previous iodinated contrast reactions, have poor renal function, are pregnant or are breast feeding. The other modalities mentioned have no definitive role in pulmonary embolism diagnosis.

#### 3. Answer: c, d and e

Pulmonary emboli are a medical emergency and should be treated as such. Patients with a high pre test probability of pulmonary emboli may be started on an empirical dose of Daltaparin while awaiting imaging. A positive scan result will require the dose to be converted to a therapeutic one, under the supervision of the acute medical team. If the patient is not on an empirical dose, it is always worth checking contraindications to thrombolysis while flagging the patient to the acute medical team.

Following senior review in appropriate cases, a thrombectomy under IR guidance may be considered, however this is performed only at specialist centres. If there is no obvious cause for the embolism, routine abdomen and pelvis scanning can be performed to rule out an occult neoplasm, though the yield of such imaging is usually low.

### Authors

#### Riddhika Chakravartty

Radiology ST2, Guildford Road, Chertsey, KY16 OPZ

#### Alastair Oakes

Radiology ST2, Royal Surrey County Hospital, Egerton Road, Guildford, GU2 7XX

#### Chandni Patel

Radiology ST2, Royal Surrey County Hospital, Egerton Road, Guildford, GU2 7XX

#### Alessandro Antonello

Core Medicine Trainee, East Surrey Hospital Canada Avenue, Redhill, RH1 5RH

#### Dr Vineet Prakash

Consultant Radiologist and Nuclear Medicine Physician Royal Surrey County NHS Foundation Trust Hospital Egerton Road, Guildford, GU2 7XX

### Corresponding Author

#### Riddhika Chakravartty

riddhika.chakravartty@nhs.net

### References

1. British Thoracic Society Guidelines for the management of suspected acute pulmonary embolism. Thorax 2018;73:ii1-ii29. doi:10.1136/thoraxjnl-2018-211539.
2. <https://www.nice.org.uk/guidance/cg144/chapter/key-priorities-for-implementation>, accessed 04 April 2018
3. <https://www.radiologyinfo.org/en/pdf/safety-xray.pdf>, accessed 04 April 2018

### Disclaimers

#### Conflict of interest

The Foundation Years Journal requires that authors disclose any potential conflict of interest that they may have. This is clearly stated in the Journal's published "Guidelines for Authors" ([https://www.123library.org/misc/FYJ\\_Guidelines\\_For\\_Authors.pdf](https://www.123library.org/misc/FYJ_Guidelines_For_Authors.pdf)). The Journal follows the Guidelines against Conflict of Interest published in the Uniform Requirements for Manuscripts Submitted to Biomedical Journals ([http://www.icmje.org/urm\\_full.pdf](http://www.icmje.org/urm_full.pdf)).

#### Financial statement

The authors of this article have not been paid. The Foundation Years Journal is financed by subscriptions and advertising. The Journal does not receive money from any other sources. The decision to accept or refuse this article for publication was free from financial considerations and was solely the responsibility of the Editorial Panel and Editor-in-Chief.

#### Patient consent statement

All pictures and investigations shown in this article are shown with the patients' consent. We require Authors to maintain patients' anonymity and to obtain consent to report investigations and pictures involving human subjects when anonymity may be compromised. The Journal follows the Guidelines of the Uniform Requirements for Manuscripts ([http://www.icmje.org/urm\\_full.pdf](http://www.icmje.org/urm_full.pdf)). The Foundation Years Journal requires in its Guidelines for Authors a statement from Authors that "the subject gave informed consent".

#### Animal & human rights

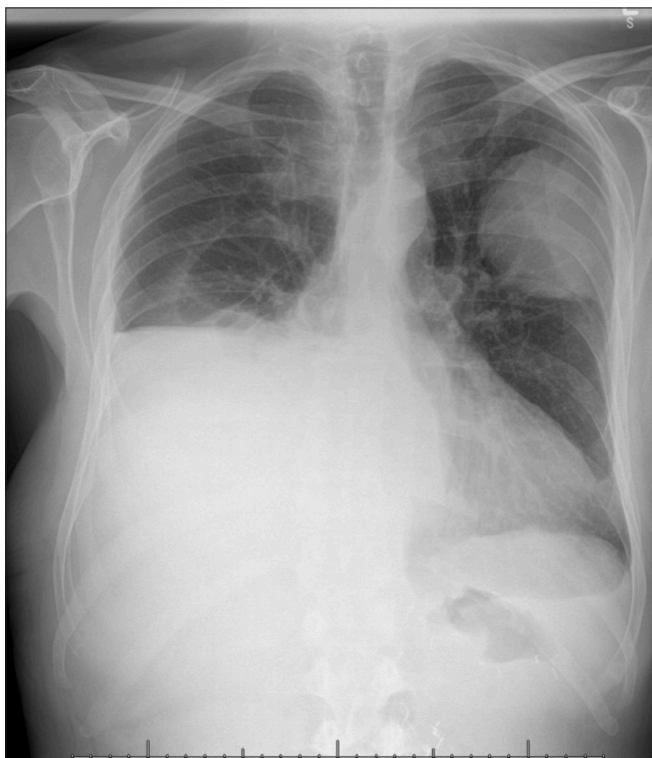
When reporting experiments on human subjects, the Foundation Years Journal requires authors to indicate whether the procedures followed were in accordance with the ethical standards of the responsible committee on human experimentation (institutional and national) and with the Helsinki Declaration of 1975, as revised in 2008.

## ARTICLE PLEURAL DRAINS TRACK CHANGES

C Patel, S Idriz, A Oakes, R Chakravartty

### Abstract

A 73 year old male patient with a background of metastatic melanoma present to accident and emergency with a progressively worsening shortness of breath. On initial assessment it was decided to perform a chest radiograph.



**Image 1: PA chest radiograph showing large right pleural effusion.**

Here is the chest radiograph. Review the film yourself prior to reading further. What do you notice first? Is there any more pathology?

From the chest radiograph it can be seen that the lower half of the right hemithorax is a white out. The density, meniscus and lack of volume loss point toward a large pleural effusion. There is also likely to be partial collapse of the right lower lobe due to compression from the large pleural effusion.

Looking now at the left hemithorax, there is a well defined density within the left upper zone. This density appears to be continuous with the pleural border and forms an obtuse angle with the lung, suggesting pleural origin. This is a pleural metastasis, which was confirmed on former PET-CT imaging.

With the patient presenting acutely with respiratory compromise, which was felt most likely secondary to the large right sided pleural effusion, the decision was made to perform an urgent ultrasound guided pleural drainage, within the radiology department.

An ultrasound guided seldinger technique was used to insert a pleural drain into the patient. A seldinger technique involves using a guide wire through an introducer needle to obtain safe access into the pleural cavity.

Prior to any invasive procedure consideration needs to be given to whether the patient has any clotting disorder or anticoagulation therapy that will increase the current risk of bleeding. Patients known to be receiving anticoagulants or in whom there is a suspected coagulopathy (eg, liver failure) should have their prothrombin time (PT) or international normalised ratio (INR) measured prior to a non-urgent pleural procedure.

The BTS guidance suggest avoiding invasive non-urgent pleural procedures until the INR is <1.5. If a patient has abnormal coagulation and requires an invasive pleural procedure, the advice of the local haematologist should be sought regarding the correct action needed to normalise the clotting.

Ensure you have carried out written consent, informing the patient about the procedure, checking for allergies and explaining the potential risks such as pneumothorax, bleeding and infection. Consent should be carried out by the doctor undertaking the procedure. If you are carrying out the procedure under supervision of a senior, ensure that your senior colleague is present during the consent process.

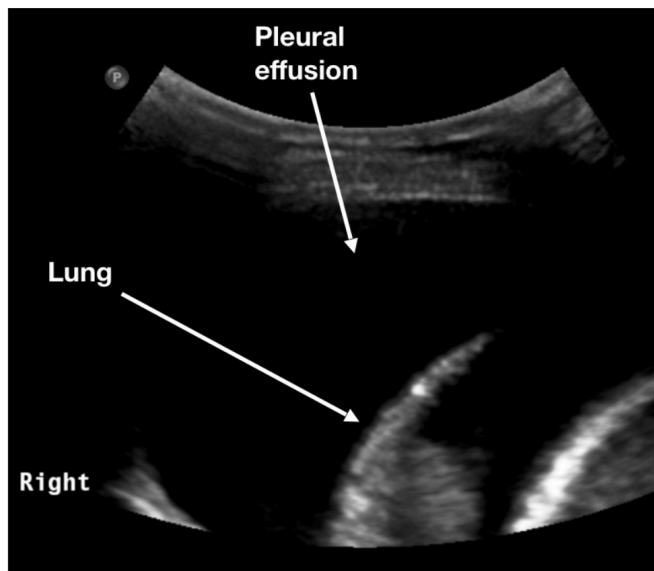
The complication of empyema or wound site infection can be reduced by following a strict aseptic technique. A large area of skin should be cleaned with alcohol based skin disinfectant. Check all the equipment is present. We use pigtail non-locking drains in the chest, usually 8 Fr, however there is scope to use larger bore in certain circumstances.

Ultrasound has been found to detect fluid more accurately than chest radiographs and is frequently used to guide insertion by those experienced in its use. When using ultrasound to guide drain insertion, ensure you have the correct ultrasound settings and appropriate probe (C5-12). Prepare the probe with lubricating gel and scan in transverse plane between rib spaces once you have orientated your probe position with image on the screen.

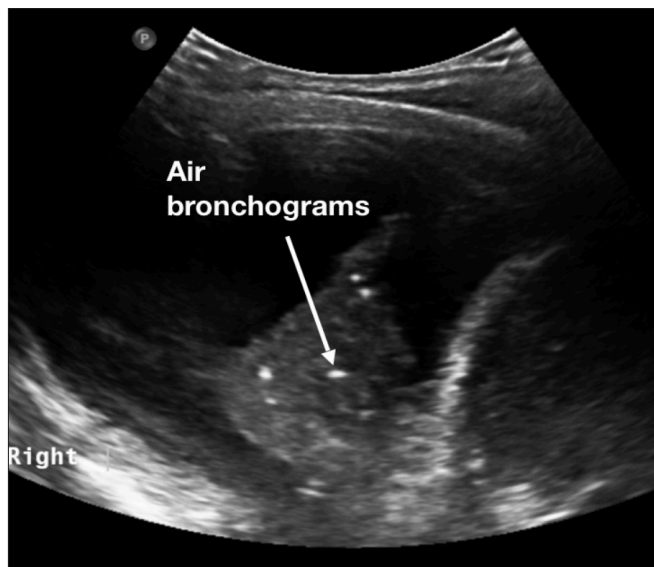
## ARTICLE PLEURAL DRAINS TRACK CHANGES

C Patel, S Idriz, A Oakes, R Chakravartty

Scan superiorly and inferiorly to the potential insertion site, looking for any adjacent structures. Mark an area appropriate for drain insertion, over the superior border of the rib (to avoid the neurovascular bundle). This is usually a space with the largest measurable effusion, with safe distance away from diaphragm/liver and adjacent collapsed lung.



**Image 2: Ultrasound image of a large right sided pleural effusion in a different patient.**



**Image 3: Ultrasound image of a right sided pleural effusion with underlying consolidated lung with air bronchograms taken from a different rib space from the same patient as image 2.**

With the patient positioned in an erect sitting position, using a curvilinear probe will give you an image like the one above. Closest to the probe you have subcutaneous tissue and skin (grey strip of tissue seen superiorly with the above image), thereafter the parietal pleura which is an almost imperceptible thin line, beyond which is the pleural fluid (black area).

Within the black area there is a brighter echogenic region, which represents the underlying collapsed lung. Visualisation of the collapsed lung allows you evaluate size and margins of the effusion. Chest Ultrasound requires formal training and forms part of the core training curriculum for radiology SpRs and most respiratory SpRs.

Once you have the correct plane, local anaesthetic (usually 1% lidocaine) is infiltrated down to the pleura and a skin bleb is formed superficially to anaesthetise the skin appropriately. Allow approximately 1 minute for the anaesthetic to take effect. With ultrasound guidance an arterial needle is inserted into the pleural effusion, aspirate once you are in the effusion.

For a seldinger technique a soft tip guideline wire is inserted through the hollow needle, the needle can then be removed whilst holding the guideline securely. Appropriately sized dilators can be used to dilate the tract, up to the size of the drain being used. The pigtail drain can then be inserted over the guideline. All sharps to be disposed of in appropriate sharps bins after the procedure.

There will be immediate drainage of the fluid into the drain bag in most cases, with some exceptions for instance if there is a loculated effusion drainage may not be seen as freely. To check the drain, you can always ask your patient to cough and watch the fluid swing in the drainage tubing. Allow free drainage for 1.5 litre and review the patient.

Drain output should be monitored for accurate fluid balance assessment and to judge whether drain is functioning appropriately whilst in situ. Clinical assessment of the patient will guide when the drain can be removed, usually once it has finished draining.

A repeat chest x-ray is not always indicated, after a simple pleural aspiration/drainage unless air is withdrawn and during the procedure you suspect a pneumothorax, or the procedure is difficult, multiple attempts are required or the patient becomes symptomatic.

## ARTICLE PLEURAL DRAINS TRACK CHANGES

C Patel, S Idriz, A Oakes, R Chakravartty

A ultrasound guided seldinger technique is one of the methods of pleural drain insertion. This article does not aim to teach the technique, but allows a basic understanding for the technique and relevant associated imaging. Please see: Pleural procedures and thoracic ultrasound: British Thoracic Society pleural disease guideline (referenced below) for comprehensive guidelines.

## Test yourself

**1) A patient presents with shortness of breath, the initial chest x-ray shows a right sided white out, with no mediastinal shift, what is your top differential diagnosis?**

- a) Pleural effusion
- b) Pneumonectomy
- c) Entire lung collapse
- d) Pneumothorax
- e) Normal appearance

**2) A patient presents with acute shortness of breath with a large pleural effusion, what is the indication for a chest drain?**

- a) The patient requests it
- b) Your consultant asks you to
- c) Acute respiratory compromise
- d) To treat bilateral pleural effusions in heart failure
- e) Chest pain

**3) What does it mean to use a seldinger technique?**

- a) Using an ultrasound machine
- b) Drain insertion over a guide wire
- c) Carrying out the drain in the radiology department
- d) Special technique which cannot be done on the ward
- e) Does not require appropriate training

**4) On ultrasound of the chest, what colour shadows would you expect to see for a simple pleural effusion?**

- a) Grey
- b) Bright white
- c) Black
- d) Red
- e) Blue

**5) When considering bleeding risk prior to invasive procedures, which patient group may require additional consideration outside of INR/coagulation profile?**

- a) Diabetic patients
- b) Paediatric patients
- c) Elderly patients
- d) Chronic liver disease patients
- e) Normal healthy patients

## Answers

**1. Answer: a)**

Pleural effusion. Without mediastinal shift there is no evidence of volume loss to suggest a lung collapse. A white out is not a normal appearance, however may be normal for a patient post pneumonectomy. Also the clue for pneumonectomy will be evidence of thoracic surgery, e.g. missing rib.

A pneumothorax does not give you a white out, it gives you a lucent area beyond the lung edge where there are no lung markings on an erect film.

**2. Answer: c)**

Acute respiratory compromise felt secondary to the large effusion would be an indication. Bilateral effusions which are felt to be secondary to heart failure are generally not treated with drainages as first line.



## ARTICLE PLEURAL DRAINS TRACK CHANGES

C Patel, S Idriz, A Oakes, R Chakravartty

### 3. Answer: b)

*Drain insertion over a guidewire. The technique allows for reduction in patient discomfort and invasiveness, and the apparent ease and safety of insertion of the smaller drains.*

*Appropriate training under supervision is required, but does not necessarily need to be carried out within a radiology department.*

### 4. Answer: c)

*Simple fluid has a black appearance on ultrasound. If there are grey shadows within the fluid it may point away from simple fluid. Sometime linear bright shadows are seen within the effusion which could indicate loculations/ septations.*

### 5. Answer: d)

*Patients with chronic liver disease can often have abnormal clotting, however the INR and PT are also often not an accurate reflection of the coagulation status. In this patient group clinical judgement needs to be used to assess their suitability for any invasive procedure. Discussion with senior registrar and/or consultants recommended prior to any invasive procedure.*

## Authors

### Dr Chandni Patel

Radiology Specialty Registrar  
Royal Surrey County Hospital  
Guildford, UK

### Dr Sanjin Idriz

Consultant Radiologist  
Royal Surrey County Hospital  
Guildford, UK

### Dr Alistair Oakes

Radiology Specialty Registrar  
Royal Surrey County Hospital  
Guildford, UK

### Dr Riddhika Chakravartty

Radiology Specialty Registrar  
Royal Surrey County Hospital  
Guildford, UK

## Corresponding Author

### Dr Chandni Patel

chandni.patel4@nhs.net

## References

1. Maskell NA, Medford A, Gleeson FV Seldinger chest drain insertion: simpler but not necessarily safer Thorax 2010;65:5-6.
2. Havelock, T, Teoh, R., Laws, D. and Gleeson, F. Pleural procedures and thoracic ultrasound: British Thoracic Society pleural disease guideline 2010 Thorax2010 65: i61-i76

## Disclaimers

### Conflict of interest

The Foundation Years Journal requires that authors disclose any potential conflict of interest that they may have. This is clearly stated in the Journal's published "Guidelines for Authors" ([https://www.123library.org/misc/FYJ\\_Guidelines\\_For\\_Authors.pdf](https://www.123library.org/misc/FYJ_Guidelines_For_Authors.pdf)). The Journal follows the Guidelines against Conflict of Interest published in the Uniform Requirements for Manuscripts Submitted to Biomedical Journals ([http://www.icmje.org/urm\\_full.pdf](http://www.icmje.org/urm_full.pdf)).

### Financial statement

The authors of this article have not been paid. The Foundation Years Journal is financed by subscriptions and advertising. The Journal does not receive money from any other sources. The decision to accept or refuse this article for publication was free from financial considerations and was solely the responsibility of the Editorial Panel and Editor-in-Chief.

### Patient consent statement

All pictures and investigations shown in this article are shown with the patients' consent. We require Authors to maintain patients' anonymity and to obtain consent to report investigations and pictures involving human subjects when anonymity may be compromised. The Journal follows the Guidelines of the Uniform Requirements for Manuscripts ([http://www.icmje.org/urm\\_full.pdf](http://www.icmje.org/urm_full.pdf)). The Foundation Years Journal requires in its Guidelines for Authors a statement from Authors that "the subject gave informed consent".

### Animal & human rights

When reporting experiments on human subjects, the Foundation Years Journal requires authors to indicate whether the procedures followed were in accordance with the ethical standards of the responsible committee on human experimentation (institutional and national) and with the Helsinki Declaration of 1975, as revised in 2008.

## SINISTRAL PORTAL HYPERTENSION: A POORLY RECOGNISED ENTITY

S Zafar, YJ Lee, F Kazmi, N Khan

### Abstract

A 51-year-old female presented acutely to hospital with recurrent episodes of upper gastrointestinal (UGI) bleeding. She had a background history of chronic pancreatitis, hepatic steatosis and diverticulosis.

She underwent an oesophago-gastroduodenoscopy (OGD) and flexible sigmoidoscopy, which did not identify an active bleeding point. During the course of her in-patient admission, she had multiple further episodes of malaena, with haemodynamic instability on each occasion. She consequently underwent triple-phase mesenteric computed tomography angiograms (CTA), on three separate occasions.

These studies did not identify an active arterial bleeding point. It was however noted that she had extensive calcification of her pancreas, gastric collaterals surrounding the fundus, and non-opacification of the splenic vein through the pancreatic tail.

A delayed diagnosis of presumed sinistral portal hypertension (SPH) secondary to splenic vein occlusion consequent to chronic pancreatitis was made. She subsequently underwent an endovascular partial splenic embolisation.

There are multiple causes of sinistral portal hypertension, of which chronic pancreatitis is one. This case illustrates the impetus for considering this rare entity in the differential diagnosis of patients with recurrent gastrointestinal tract (GIT) bleeding, so as to facilitate making the correct clinical and radiological diagnosis in a timely manner.

Though well recognized by hepatobiliary clinicians and interventional radiologists, this may be a perplexing pathology for junior doctors and trainee radiologists alike. We thus seek to provide a review of this disease entity and considerations in management, with graphic and pictorial illustrations and reference to our case.

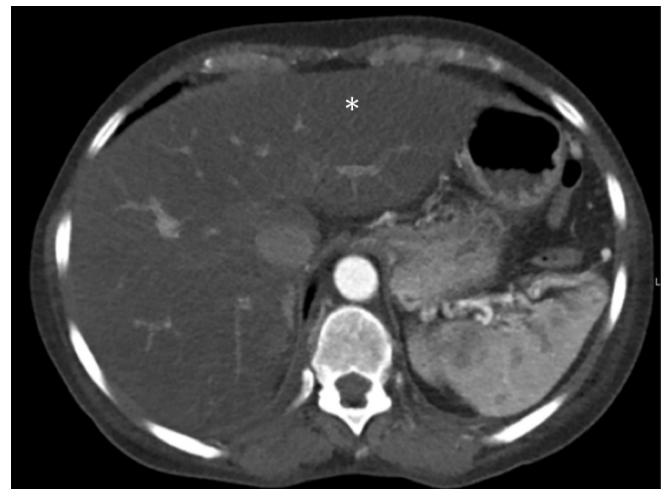
### Background

Greenwald and Wasch, in 1939, described the pathophysiology of sinistral portal hypertension (SPH), which classically presents with upper gastrointestinal (UGI) bleeding. (1) (2) Characterised by splenic vein occlusion, this rare pathology has been linked to a number of underlying etiologies. (3)

Recognising this entity when it does occur, by accurate interpretation of the imaging along with careful consideration of the clinical context, is therefore essential as the course of treatment in these cases may differ entirely from conventional management of patients with acute UGI bleeding related to portal hypertension. (4)

### Case

A 51-year-old female presented to the emergency department in February 2018 with an acute UGI bleed. She had a prior medical history of recurrent episodes of alcoholic pancreatitis, diffuse hepatic steatosis, and extensive sigmoid colonic diverticular disease.



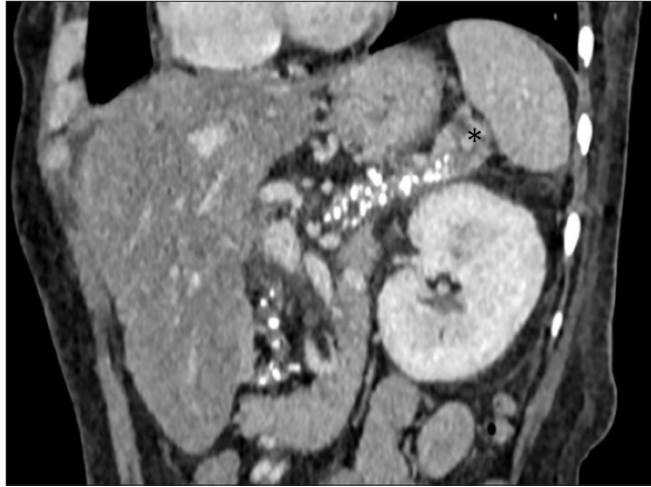**Figure 1: Axial CT image demonstrating diffusely reduced hepatic attenuation, consistent with hepatic steatosis (white asterisk).**

Salient findings on clinical examination included malaena mixed with bright red blood per rectum. She was haemodynamically unstable with a haemoglobin of 6 g/dl. An oesophago-gastroduodenoscopy (OGD) and flexible sigmoidoscopy were both undertaken, which did not identify an active bleeding point.

She was subsequently transfused four units of packed red cells (PRC). Initial triple-phase computed tomography mesenteric angiogram (CTA) did not reveal an active bleeding point however did demonstrate extensive calcification of her pancreas, multiple varices surrounding the gastric fundus and non-opacification of the splenic vein through the tail of the pancreas.

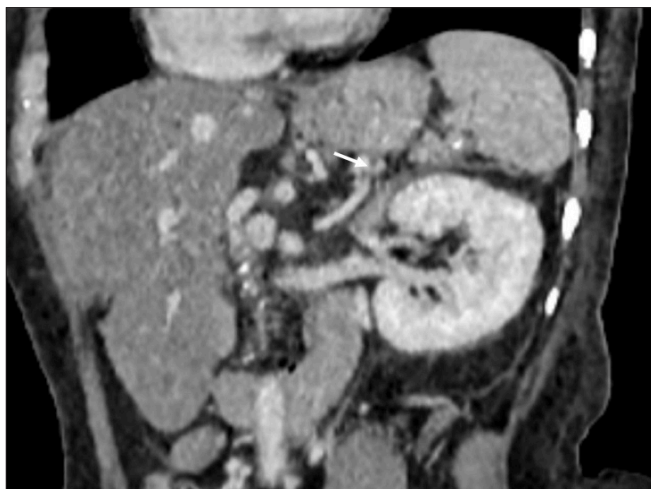## SINISTRAL PORTAL HYPERTENSION: A POORLY RECOGNISED ENTITY

S Zafar, YJ Lee, F Kazmi, N Khan



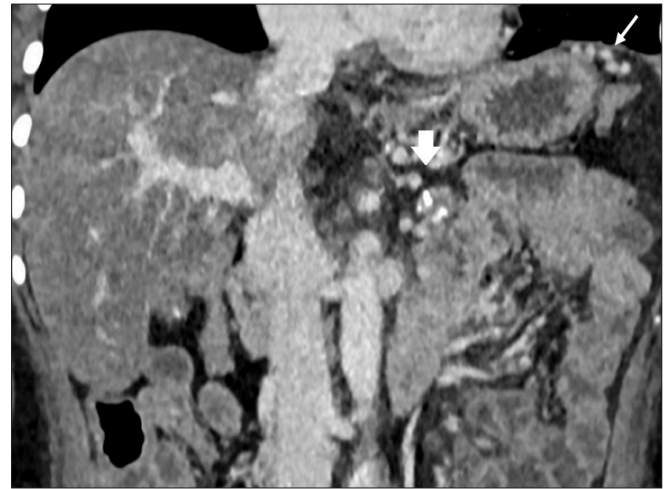
**Figure 2:** Oblique multi-planar reformat CT image in the portal venous phase, demonstrating extensive pancreatic calcification with moderate dilatation of the pancreatic duct in the tail of the pancreas, consistent with chronic pancreatitis (black asterisk).

The patient was managed in hospital over the course of the next 35 days, during which time she experienced multiple further episodes of UGI bleeding with large volume melaena. Repeat endoscopic and two further mesenteric CTA investigations were negative. The patient again received multiple transfusions including 12 further units of PRC, 7 units of fresh frozen plasma (FFP), 2 units of cryoprecipitate (CRYO) and 3 pools of platelets (PLTS), to correct her anaemia, thrombocytopenia and coagulopathy.



**Figure 3:** Oblique CT demonstrating abrupt cut off and non-opacification of the splenic vein through the pancreatic tail, consistent with the presumptive diagnosis of SPH (white arrow).

Following this, the patient's case was discussed at the Upper GI multi-disciplinary team meeting (MDT), where upon review, the poor opacification of her splenic vein, which had been duly noted on all three prior CTAs, was related to chronic splenic vein occlusion. She was given a presumptive diagnosis of sinistral portal hypertension (SPH), secondary to chronic splenic vein occlusion. The aetiology of this was related to her chronic pancreatitis.



**Figure 4:** Coronal CT of the upper abdomen demonstrating multiple collateral veins surrounding the gastric fundus (thin white arrow), communicating with the left gastric vein (thick white arrow).

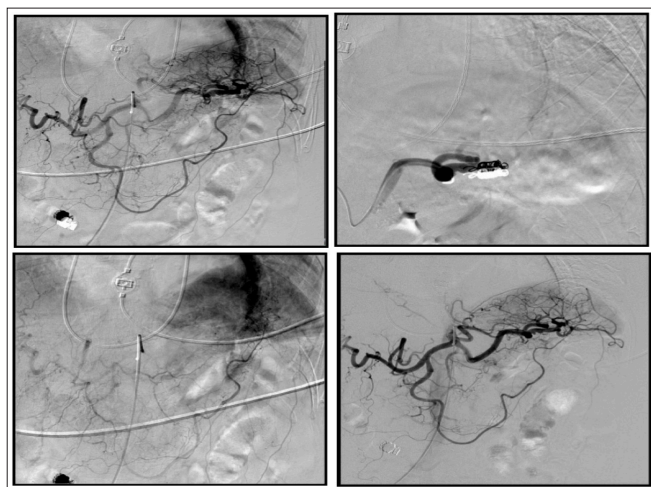
The patient subsequently underwent an endovascular partial splenic embolisation under antibiotic cover. This was undertaken 7 weeks following her initial presentation. Vascular access was obtained via a right common femoral artery puncture.

A 5-French sheath was positioned at the groin. The splenic artery was cannulated with a co-axial system and approximately 70% of the spleen was embolised with a combination of particles (polyvinyl alcohol, 700-1000  $\mu$ m diameter, 1.5 phials) and 6 mm Micro Nester coils, deployed into the distal splenic artery.

## SINISTRAL PORTAL HYPERTENSION: A POORLY RECOGNISED ENTITY

S Zafar, YJ Lee, F Kazmi, N Khan

A repeat CT abdomen and pelvis at 7 days post-procedure demonstrated a partial splenic infarct with no evidence of abscess or sub-capsular fluid collection. The patient made good progress following this with no further episodes of UGI bleeding. She was subsequently discharged home.



**Figure 6: Selective cannulation of the splenic artery (left hand panel) with subsequent coil and particulate embolisation (right hand panel).**

### Discussion

Sinistral portal hypertension (SPH), also known as left-sided, segmental or compartmental portal hypertension is a rare cause of UGI bleeding, accounting for <1% of cases. (5) (6) Characteristically due to splenic vein thrombosis (SVT) or occlusion (SVO), Greenwald and Wasch describe the onset of increased pressures within the splenic venous bed.

The resultant increased pressures and flow in the gastric and gastroepiploic veins leads to the eventual formation of spleno-gastric varices. (1) The portal vein typically remains patent and paradoxically, portal pressures also remain within normal limits, hence oesophageal varices are less common. (7) The typical presentation of SPH is thus with an UGI bleed, however many patients in the literature are asymptomatic or complain of chronic, non-specific abdominal pain. (8)

There is a broad list of underlying causative aetiologies which have been linked to SPH including: acute and chronic pancreatitis, pancreatic neoplasms, iatrogenic injury to the splenic vein following orthotopic liver transplantation, retroperitoneal fibrosis, hereditary thrombophilias, splenic lymphoma with associated SVT, peri-renal abscesses, and rarely abdominal or retroperitoneal tuberculosis. (3) (6)

Chronic pancreatitis, as was the case in our patient, and neoplasms within the pancreas are reported to be the most common underlying aetiology, likely due to the close proximity of the splenic vein to the undersurface of the pancreas. (3) (6)

It is recognized in the literature that patients with SPH are often initially misdiagnosed due to the common misconception that the gastric varices are related to an underlying hepatic aetiology, with secondary portal hypertension. Furthermore, small fundal gastric varices may not be identified on oesophago-gastroduodenoscopy, contributing to missed diagnoses. (4)

In the case of our patient, SPH was not considered in the differential diagnosis until several weeks from initial presentation, by which time the patient had already undergone multiple CT mesenteric angiograms, exposing her to approximately 20 mSv of unwarranted radiation - equivalent to approximately 3 years of background radiation. She also received multiple intravenous blood product transfusions (total of 16 PRC, 7 FFP, 2 CRYO, 3 PLT), which is not without risk in itself.

There was thus a significant delay in instituting appropriate management due to initial misdiagnosis in our case. Correction of the underlying cause of the SPH usually constitutes the mainstay of management of SPH. Historically, splenectomy used to be advocated however with the advent of interventional radiology and endovascular therapies, partial splenic artery embolisation (SAE) should be considered as a first line treatment in select patients, namely those whom are actively bleeding or are unfit for splenectomy. (2) (5) (6).

SAE achieves an overall reduction in arterial inflow to the spleen, lowering pressures in the splenic venous collaterals, thereby significantly reducing flow in the gastric varices. It is a minimally invasive procedure, which is fast and effective with a rapid recovery time and low complication rate, avoiding the risks from undergoing major surgery under general anesthetic.

## SINISTRAL PORTAL HYPERTENSION: A POORLY RECOGNISED ENTITY

S Zafar, YJ Lee, F Kazmi, N Khan

It is essential to be mindful of the possible complications however and recognising post-splenic embolisation syndrome (PSES) is crucial. This is characterised by pyrexia, abdominal pain, leukocytosis and abscess. Administering vaccinations pre-procedure and delivering prophylactic intravenous antibiotics intra-procedurally must not be overlooked, particularly in the context of total splenic embolisation. (7) (9)

### Conclusion

Sinistral portal hypertension, although a rare disease entity, must be considered in the differential diagnosis when managing patients presenting acutely with an upper GI bleed. SPH is multi-factorial in aetiology, however most often related to an underlying pancreatic pathology.

It is important to differentiate this entity from other causes of acute UGI bleeding, namely portal hypertension, as the course of treatment in these cases may be entirely different.

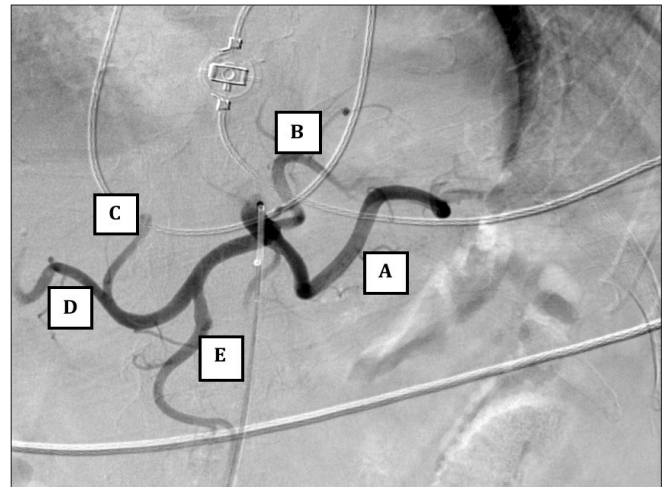
### Teaching Points

- **Not all variceal bleeds are secondary to hepatic cirrhosis, remember to consider other causes.**
- **Review the porto-splenic vascular bed closely, to ensure there is no chronic splenic or portal vein occlusion.**
- **Be aware of splenic vein occlusion in the context of chronic pancreatitis as a cause of recurrent upper GI bleeds.**
- **Consider splenic artery embolisation as first line management for gastric varices related to sinistral portal hypertension.**

Best of 5 MCQs:

1. With reference to the labeled angiogram below, select the label which best corresponds to the splenic artery?

- A
- B
- C
- D
- E



Angiographic image with catheter in the coeliac trunk. Labels correspond to: A splenic artery, B left gastric artery, C left hepatic artery, D right hepatic artery, E gastroduodenal artery.

2. Which of the following is not a recognised indication for a splenic artery embolisation:

- Sinistral portal hypertension
- Thrombocytopenia
- Splenic haemangioma
- Traumatic splenic rupture
- Splenic artery pseudoaneurysm.

3. Which of the following vaccinations is not routinely administered in the post-splenectomy period to reduce the risk of overwhelming post-splenectomy sepsis?

- Pneumococcus
- Haemophilus influenza
- Influenza
- Hepatitis B
- Meningococcal



## SINISTRAL PORTAL HYPERTENSION: A POORLY RECOGNISED ENTITY

S Zafar, YJ Lee, F Kazmi, N Khan

### Answers

1. **Correct Answer: A.**

2. **Answer: C**

3. **Answer: D**

### Authors

#### Dr Sara Zafar

Specialist Registrar  
Radiology Department  
Chelsea and Westminster Hospital  
369 Fulham Road, London, SW10 9NH  
United Kingdom

#### Dr Yu Jin Lee

Specialist Registrar  
Radiology Department  
Great Ormond Street Hospital, London  
Yujin.Lee@chelwest.nhs.uk

#### Dr Farhat Kazmi

Consultant Radiologist  
Radiology Department  
Chelsea and Westminster Hospital  
369 Fulham Road, London, SW10 9NH  
United Kingdom  
Farhat.kazmi@chelwest.nhs.uk

#### Dr Nasir Khan

Consultant Radiologist  
Radiology Department  
Chelsea and Westminster Hospital  
369 Fulham Road, London, SW10 9NH  
United Kingdom  
nasir.khan@chelwest.nhs.uk

### Corresponding Author

#### Dr Sara Zafar

sarazafar@nhs.net

### References

- (1) Greenwald HM, Wasch MG. The roentgenologic demonstration of oesophageal varices as a diagnostic aid in chronic thrombosis of the splenic vein. *J Pediatr.* 1939; 14:57-65.
- (2) Wang L, Liu GJ, Chen YX, Dong HP, Wang LX. Sinistral portal hypertension: clinical features and surgical treatment of chronic splenic vein occlusion. *Med Princ Pract.* 2012; 21:20-23.
- (3) Singhal D, Kakodkar R, Soin A, Gupta S, Nundy S. Sinistral Portal Hypertension. A Case Report. *JOP.* 2006; 7(6): 670-67.
- (4) Kokabi N, Lee E, Eschevarria C, Loh C, Kee S. Sinistral Portal Hypertension: Presentation, Radiological Findings, and Treatment Options – A Case Report. *J Radiol Case Rep.* 2010; 4(10): 14-20.
- (5) Koklu S, Coban S, Yuksel O, Arhan M. Left-Sided Portal Hypertension. *Dig Dis Sci.* 2007; 52:1141-1149.
- (6) Thompson R, Taylor M, McKie L, Diamond T. Sinistral Portal Hypertension. *Ulcer Med J.* 2006; 75:175-177.
- (7) Fernandes A, Almeida N, Margardia A e al. Left-Sided Portal Hypertension: A Sinister Entity. *GE Port J Gastroenterol.* 2015 Nov-Dec; 22(6): 234-239.
- (8) Agarwal A, Kumar R, Agarwal S, Sing S. Significance of Splenic Vein Thrombosis in Chronic Pancreatitis. *Am J Surg.* 2008; 196:149-154.
- (9) Cakmak O, Parildar M, Oran I, Sever A, Memis A. Sinistral portal hypertension: imaging findings and endovascular therapy. *Abdom Imaging.* 2005;30:208-213.

### Disclaimers

#### Conflict of interest

The Foundation Years Journal requires that authors disclose any potential conflict of interest that they may have. This is clearly stated in the Journal's published "Guidelines for Authors" ([https://www.123library.org/misc/FYJ\\_Guidelines\\_For\\_Authors.pdf](https://www.123library.org/misc/FYJ_Guidelines_For_Authors.pdf)). The Journal follows the Guidelines against Conflict of Interest published in the Uniform Requirements for Manuscripts Submitted to Biomedical Journals ([http://www.icmje.org/urm\\_full.pdf](http://www.icmje.org/urm_full.pdf)).

#### Financial statement

The authors of this article have not been paid. The Foundation Years Journal is financed by subscriptions and advertising. The Journal does not receive money from any other sources. The decision to accept or refuse this article for publication was free from financial considerations and was solely the responsibility of the Editorial Panel and Editor-in-Chief.

#### Patient consent statement

All pictures and investigations shown in this article are shown with the patients' consent. We require Authors to maintain patients' anonymity and to obtain consent to report investigations and pictures involving human subjects when anonymity may be compromised. The Journal follows the Guidelines of the Uniform Requirements for Manuscripts ([http://www.icmje.org/urm\\_full.pdf](http://www.icmje.org/urm_full.pdf)). The Foundation Years Journal requires in its Guidelines for Authors a statement from Authors that "the subject gave informed consent".

#### Animal & human rights

When reporting experiments on human subjects, the Foundation Years Journal requires authors to indicate whether the procedures followed were in accordance with the ethical standards of the responsible committee on human experimentation (institutional and national) and with the Helsinki Declaration of 1975, as revised in 2008.

## FOUNDATION DOCTORS' KNOWLEDGE OF RADIATION LEGISLATION & EXPOSURE

M Adil, S Tanzeem, H Raza, M Vassallo

### Abstract

#### Objective

To assess the knowledge and awareness of legislation surrounding radiations and knowledge of dosages associated with common radiological investigations amongst foundation trainees.

#### Methodology

A quantitative survey in which 62 foundation doctors were asked to fill in a questionnaire which included questions related to radiation legislations and radiation exposure, in yes/no format and to give an estimated knowledge and awareness, in terms of radiation dose, of most common radiological investigations.

#### Results

In total 43.5% doctors did not know about any governmental regulations on radiation exposure and 21% were unaware of their legal obligation to provide accurate information when requesting radiological investigations. More than half (51.6%) of the foundation trainees were unaware of the fact that the Department of Radiology has a right to withdraw radiology ordering rights.

The radiation doses knowledge was meagre, only 5-8% gave correct answer and 80% underestimated the dose of radiological examinations. Most important to note, 61.4% foundation trainees had been asked by their senior colleagues to request radiological investigations while they were unsure about the indication of investigation. 40% felt they had inadequate teaching regarding appropriate radiology referrals.

#### Conclusion

Majority of the foundation trainees had inadequate knowledge on radiation legislations, and particularly scarce on radiation doses of common radiological investigations. A large proportion of foundation trainees were unsure of the indication for investigations requested by their senior colleagues and felt inadequately trained in this regard.

This clearly indicates that there's more need for education of foundation trainees about radiology legislation and radiation exposure during their training years but perhaps also during medical school.

### Background

Medical diagnosis has been revolutionized since the discovery of diagnostic radiation by Wilhelm Conrad Röntgen, in 1895 (1). Due to evolution of technology and growth of the medical imaging industry, there's been an increasing trend of doctors' requesting radiological investigations to aid clinical diagnosis and to offer best treatment options to their patients.

This has not only benefitted in providing better patient care and treatment outcomes but also put doctors at a challenge in their day to day clinical practice, to maximize the risk-benefit ratio surrounding the radiation exposure (2).

A number of studies have showed that amongst the medical community, in general, there is little cognizance regards the amount of radiation patients are exposed to and poor discernment of indication for radiological requests (3-6).

Doctors have a legal obligation to comply with The Ionising Radiation (Medical Exposure) Regulations (IRMER) 2000 (Amended 2006 and 2011) issued by the Department of Health (7), which covers in-depth all aspects of patient safety surrounding radiation exposure. 'Good Medical Practice' published by General Medical Council (8), provides an excellent model framework which ensures patient safety.

The Foundation Programme Curriculum 2016, approved by General Medical Council, requires trainees to practice in accordance with relevant legislation (9). Royal College of Radiologists have also published an essential radiological investigation guidelines tool, iRefer: Making the best use of clinical radiology (10), which provides practical guidance based on the best available evidence.

Foundation years training helps newly graduated doctors in equipping the generic skills and professional capabilities to progress to specialty training. It also helps them to establish their professional identity in the workplace and to integrate and work effectively within multidisciplinary teams and the healthcare system as a whole.

Therefore, it is important that foundation trainees should be aware of legislation surrounding radiation and have some knowledge of radiation doses of common radiological investigations.

## FOUNDATION DOCTORS' KNOWLEDGE OF RADIATION LEGISLATION & EXPOSURE

M Adil, S Tanzeem, H Raza, M Vassallo

### Limitations of the survey

- The survey was conducted in one district general hospital and only involved trainee foundation doctors, therefore the results may not be generalised.
- The questionnaire design covering radiation regulation required answers in yes/no and may not reflect the depth and understanding of the content.
- As with all questionnaires, the results are limited by the diligence of the individuals filling it.

### Methodology

A quantitative questionnaire survey of the foundation doctors' knowledge about radiation legislations and the dosage of commonly performed radiological investigations at Royal Bournemouth Hospital, England. In total, 62 foundation doctors were personally approached to fill the questionnaire and all of them filled it.

The participants were asked if they were aware of any governmental regulations on radiation, legal obligation surrounding radiological imaging requests and natural background radiation. The doctors were then asked to estimate the doses of radiation (measured in chest x-ray equivalents) for common radiological investigations.

Also if they have been asked by a senior colleague to request an investigation for which they were unsure of the indication and if they have had adequate teaching regarding appropriate radiology referrals. See Appendix A for questionnaire.

## Results

### A. Radiation and Regulations

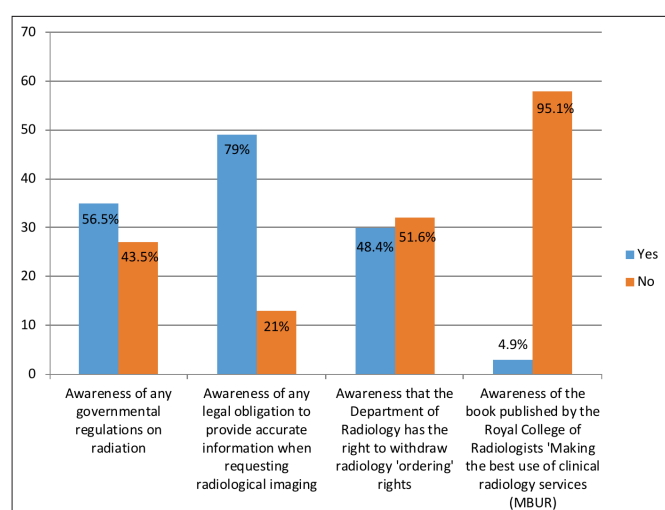


Table 1: Radiation and Regulations Results

### B. Radiation Doses

Table 2 shows the results of the estimated equivalent number of chest x-rays in terms of radiation dose (typical effective dose, mSv) for most commonly requested investigations.

Radiological Investigation	Equivalent No of chest x-rays	No of correct answers [n=62] (%)
Abdominal x-ray	35	3 (5%)
CT Head	100	5 (8%)
CT Thorax	400	0
CT abdomen/pelvis	500	0

Table 2: Radiation Doses Results

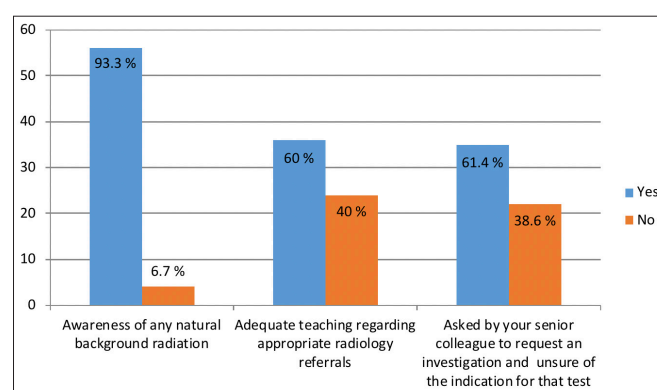


Table 3: Other Results

### Discussion

A large proportion of foundation trainees had no knowledge on radiation legislation. Radiation doses data showed minimal understanding and most trainees underestimated the doses of common radiological investigations.

Greater number of foundation trainees felt unsure of the indication for investigations requested by their senior colleagues and a moderate number of trainees felt inadequately trained in this regard. The underestimation of radiation doses may result in increased exposure to radiation hazards potentially due to excessive radiological investigations, causing serious implications to the patients.

Although this survey involved trainees in one district general hospital nevertheless they come from different medical schools all across the country, therefore the results may be reflected towards all UK foundation trainees.

## FOUNDATION DOCTORS' KNOWLEDGE OF RADIATION LEGISLATION & EXPOSURE

M Adil, S Tanzeem, H Raza, M Vassallo

### Recommendations

- Information on radiation legislation and radiation doses should be made an integral part of medical student teaching sessions and new medical staff induction sessions.
- Visual reminders such as posters should be installed in clinical areas and within Radiology department and other rooms e.g. Conference rooms.
- Regular re-audits should be carried out to monitor the effectiveness of methods employed to improve awareness amongst doctors.

### Appendix A

providing the excellent care we would expect for our own families

The Royal Bournemouth and Christchurch Hospitals  
NHS Foundation Trust

**Foundation Doctors  
Radiation Legislation Awareness Questionnaire**

This form will be scanned in electronically. Please complete in BLACK ink and put a cross (X) in the appropriate box(es). Please write all letters and numbers clearly.

Radiation and Regulations	Yes	No
1. Are you aware of any governmental regulations on radiation?	<input type="checkbox"/>	<input type="checkbox"/>
2. Are you aware of any legal obligation to provide accurate information when requesting radiological imaging?	<input type="checkbox"/>	<input type="checkbox"/>
3. Are you aware that the Department of Radiology has the right to withdraw radiology 'ordering' rights?	<input type="checkbox"/>	<input type="checkbox"/>
4. Are you aware of the book published by the Royal College of Radiologists 'Making the best use of clinical radiology services (MBUR)'?	<input type="checkbox"/>	<input type="checkbox"/>
If yes, have you ever referred to the document in your clinical practice?	<input type="checkbox"/>	<input type="checkbox"/>

Radiation Doses	Yes	No
5. Are you aware of any natural background radiation?	<input type="checkbox"/>	<input type="checkbox"/>
6. Please give an estimated number of equivalent numbers of chest x-rays in terms of radiation dose (typical effective dose, mSv) from the following diagnostic medical exposure?		
AXR	<input type="checkbox"/>	<input type="checkbox"/>
CT head	<input type="checkbox"/>	<input type="checkbox"/>
CT thorax	<input type="checkbox"/>	<input type="checkbox"/>
CT abdomen/pelvis	<input type="checkbox"/>	<input type="checkbox"/>
7. Have you been asked by your senior colleague to request an investigation and are unsure of the indication for this test?	<input type="checkbox"/>	<input type="checkbox"/>
8. Do you feel you have had adequate teaching regarding appropriate radiology referrals?	<input type="checkbox"/>	<input type="checkbox"/>

Thank you very much

Project 2910 Page 1 of 1

Clinical Audit Dept (66) Oct 4/27

### Authors

#### Maryam Adil

Senior House Officer  
The Royal Bournemouth Hospital  
Castle Lane East  
Bournemouth  
BH7 7DW

#### S Tanzeem H Raza

Consultant Physician  
The Royal Bournemouth Hospital  
Castle Lane East  
Bournemouth  
BH7 7DW  
tanzeem.raza@rbch.nhs.uk

#### Michael Vassallo

Consultant Geriatrician  
The Royal Bournemouth Hospital  
Castle Lane East  
Bournemouth  
BH7 7DW  
michael.vassallo@rbch.nhs.uk

### Corresponding Author

#### Maryam Adil

maryamsultan08@gmail.com

## FOUNDATION DOCTORS' KNOWLEDGE OF RADIATION LEGISLATION & EXPOSURE

M Adil, S Tanzeem, H Raza, M Vassallo

### References

1. [https://www.nobelprize.org/nobel\\_prizes/physics/laureates/1901/roentgen-facts.html](https://www.nobelprize.org/nobel_prizes/physics/laureates/1901/roentgen-facts.html).
2. Hricak H, Brenner DJ, Adelstein SJ, Frush DP, Hall EJ, Howell RW, McCollough CH, Mettler FA, Pearce MS, Suleiman OH, Thrall JH, Wagner LK. Managing radiation use in medical imaging: a multifaceted challenge. *Radiology*. 2011 Mar;258(3):889-905.
3. S Shiralkar, A Rennie, M Snow, R B Galland, M H Lewis, K Gower-Thomas, Doctors' knowledge of radiation exposure: questionnaire survey. *BMJ* 2003;327:371-2.
4. Brown N, Jones L. Knowledge of medical imaging radiation dose and risk among doctors. *J Med Imaging Radiat Oncol*. 2013 Feb;57(1):8-14.
5. ArslanoDlu A, Bilgin S, Kubal Z, Ceyhan MN, Ilhan MN, Maral I. Doctors' and intern doctors' knowledge about patients' ionizing radiation exposure doses during common radiological examinations. *Diagn Interv Radiol*. 2007 Jun;13(2):53-5.
6. Heyer CM, Peters S, Lemburg S, Nicolas V. [Awareness of radiation exposure of thoracic CT scans and conventional radiographs: what do non-radiologists know?]. *Rofo*. 2007 Mar;179(3):261-7.
7. The Ionising Radiation (Medical Exposure) Regulations 2000. <https://www.gov.uk/government/publications/the-ionising-radiation-medical-exposure-regulations-2000>. The Ionising Radiation (Medical Exposure) (Amendment) Regulations 2011. <https://www.legislation.gov.uk/uksi/2011/1567/contents/made>.
8. The General Medical Council, Good Medical Practice (2013).
9. <http://www.foundationprogramme.nhs.uk/curriculum/Syllabus> (Section1.3).
10. iRefer. Making the best use of clinical radiology. Royal College of Radiologists. London. 2012. <http://guidelines.irefer.org.uk/>.

### Disclaimers

#### Conflict of interest

The Foundation Years Journal requires that authors disclose any potential conflict of interest that they may have. This is clearly stated in the Journal's published "Guidelines for Authors" ([https://www.123library.org/misc/FYJ\\_Guidelines\\_For\\_Authors.pdf](https://www.123library.org/misc/FYJ_Guidelines_For_Authors.pdf)). The Journal follows the Guidelines against Conflict of Interest published in the Uniform Requirements for Manuscripts Submitted to Biomedical Journals ([http://www.icmje.org/urm\\_full.pdf](http://www.icmje.org/urm_full.pdf)).

#### Financial statement

The authors of this article have not been paid. The Foundation Years Journal is financed by subscriptions and advertising. The Journal does not receive money from any other sources. The decision to accept or refuse this article for publication was free from financial considerations and was solely the responsibility of the Editorial Panel and Editor-in-Chief.

#### Patient consent statement

All pictures and investigations shown in this article are shown with the patients' consent. We require Authors to maintain patients' anonymity and to obtain consent to report investigations and pictures involving human subjects when anonymity may be compromised. The Journal follows the Guidelines of the Uniform Requirements for Manuscripts ([http://www.icmje.org/urm\\_full.pdf](http://www.icmje.org/urm_full.pdf)). The Foundation Years Journal requires in its Guidelines for Authors a statement from Authors that "the subject gave informed consent".

#### Animal & human rights

When reporting experiments on human subjects, the Foundation Years Journal requires authors to indicate whether the procedures followed were in accordance with the ethical standards of the responsible committee on human experimentation (institutional and national) and with the Helsinki Declaration of 1975, as revised in 2008.



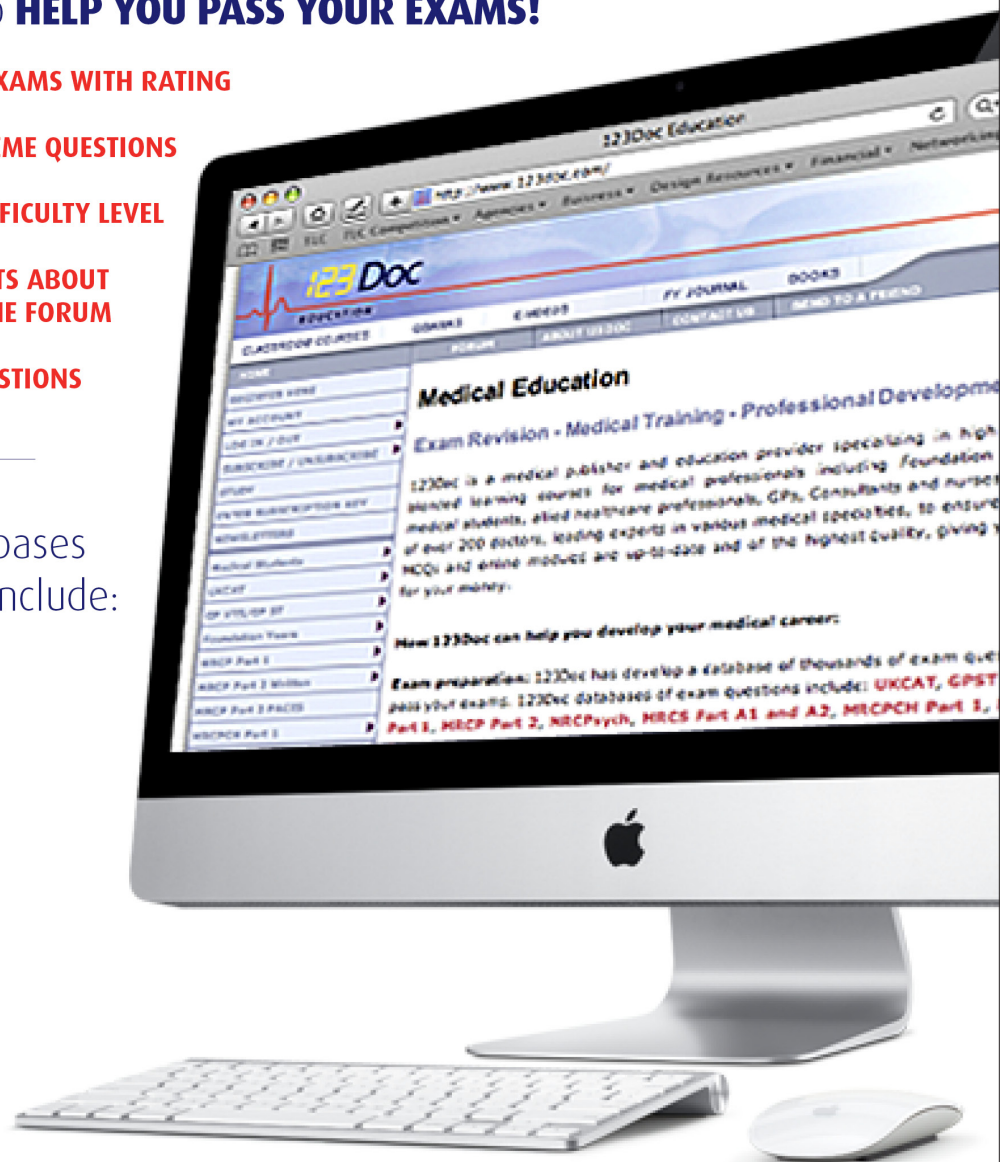
# ONLINE COURSES. YOUR REVISION'S LIFELINE.

**123DOC.COM** has developed a database of thousands of exam questions to **HELP YOU PASS YOUR EXAMS!**

- **UNLIMITED TIMED MOCK EXAMS WITH RATING**
- **100+ NEW PAST EXAM THEME QUESTIONS**
- **STUDY BY TOPIC OR BY DIFFICULTY LEVEL**
- **OPTION TO POST COMMENTS ABOUT A QUESTION TO OUR ONLINE FORUM**
- **THOUSANDS OF EXAM QUESTIONS**

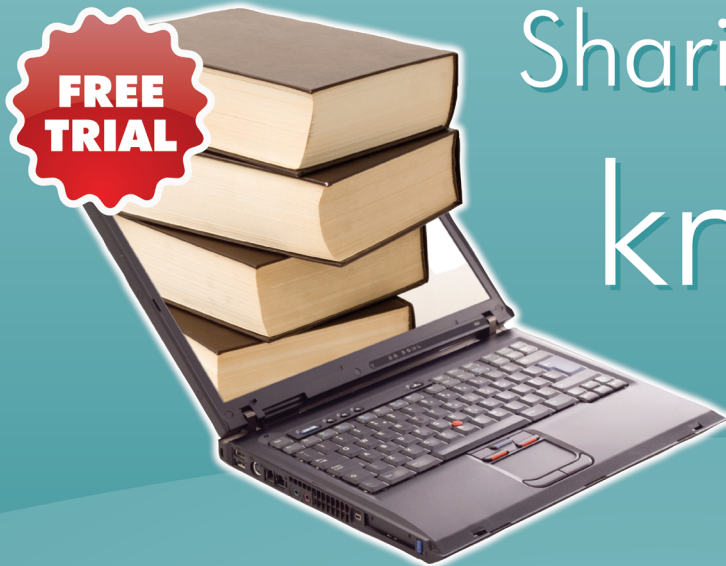**123DOC.COM** databases of exam questions include:

- ✓ **UKCAT**
- ✓ **GPST / GPVTS**
- ✓ **MRCP Part 1**
- ✓ **MRCP Part 2**
- ✓ **MRC Psych**
- ✓ **MRCSE Part A1 and A2**
- ✓ **MRCPCCH Part 1**
- ✓ **MRCPCCH Part 2**
- ✓ **FRCA Primary**
- ✓ **Primary FRCR**
- ✓ **PLAB Part 1**
- ✓ **Medical Student**
- ✓ **MRCOG**



**123Doc.com**

ONLINE COURSES



## Sharing **more** knowledge



## What is 123Library?

Contact us on  
0207 253 4363  
or email  
[sales@123library.org](mailto:sales@123library.org)  
for a  
**FREE TRIAL**

123Library is a fast growing and innovative eBook and **digital content provider for libraries** in the field of healthcare.

## What are the benefits for your library?

- 1 FULL FLEXIBILITY ✓
- 2 KNOWLEDGE ✓
- 3 CUSTOMER CARE ✓
- 4 NO HASSLES ✓
- 5 FULL SECURITY ✓
- 6 GET FEEDBACK ✓
- 7 SUPPORT ✓
- 8 EASE OF USE ✓
- 9 SAVING MONEY ✓

Benefit today, visit [www.123Library.org](http://www.123Library.org)

Subscribe to the Foundation Years Journal, visit [www.123library.org](http://www.123library.org)  
For more info call **0203 0313 866** or email [sales@123library.org](mailto:sales@123library.org)

## Volume 12, Issue 5: Orthopaedics & Radiology

### 2018 Past Issues

Volume 12, Issue 4: Ophthalmology  
Volume 12, Issue 3: Paediatrics & Respiratory  
Volume 12, Issue 2: Cardiology & Oncology  
Volume 12, Issue 1: Accident & Emergencies + Vascular Disease

### 2017 Past Issues

Volume 11, Issue 10: Dermatology, Diabetes & Endocrinology + Palliative Care & Gastroenterology  
Volume 11, Issue 9: General Medicine & Mental Health  
Volume 11, Issue 8: General Surgery  
Volume 11, Issue 7: Haematology, Palliative Care & Geriatrics  
Volume 11, Issue 6: Immunology, Infectious Disease, Nephrology & Rheumatology  
Volume 11, Issue 5: Anaesthesia  
Volume 11, Issue 4: Urology  
Volume 11, Issue 3: Obstetrics & Gynaecology  
Volume 11, Issue 2: Radiology & Rheumatology  
Volume 11, Issue 1: Ophthalmology & Pediatrics

### 2016 Past Issues

Volume 10, Issue 10: Diabetes & Endocrinology + Gastroenterology  
Volume 10, Issue 9: Orthopaedics  
Volume 10, Issue 8: Cardiology & Maxillofacial  
Volume 10, Issue 7: Respiratory  
Volume 10, Issue 6: Oncology  
Volume 10, Issue 5: Palliative Care & ENT  
Volume 10, Issue 4: Accident & Emergency & Dermatology  
Volume 10, Issue 3: Vascular Disease  
Volume 10, Issue 2: Neurology  
Volume 10, Issue 1: Psychiatry

### 2015 Past Issues

Volume 9, Issue 10: Rheumatology  
Volume 9, Issue 9: Anaesthesia (Part 2)  
Volume 9, Issue 8: Anaesthesia (Part 1)  
Volume 9, Issue 7: General Surgery  
Volume 9, Issue 6: Ophthalmology  
Volume 9, Issue 5: Infectious Diseases & Nephrology  
Volume 9, Issue 4: Respiratory  
Volume 9, Issue 3: Haematology  
Volume 9, Issue 2: Gastroenterology  
Volume 9, Issue 1: Urology - Part 2

### 2014 Past Issues

Volume 8, Issue 10: Urology - Part 1  
Volume 8, Issue 9: Obstetrics & Gynaecology - Part 2  
Volume 8, Issue 8: Paediatrics - Part 2  
Volume 8, Issue 7: Obstetrics & Gynaecology - Part 1  
Volume 8, Issue 6: Paediatrics - Part 1  
Volume 8, Issue 5: Diabetes & Endocrinology  
Volume 8, Issue 4: Immunology & Nephrology  
Volume 8, Issue 3: Neurology - Part 2  
Volume 8, Issue 2: Cardiology - Part 2  
Volume 8, Issue 1: Radiology - Part 2

### 2013 Past Issues

Volume 7, Issue 10: Vascular Disease - Part 2  
Volume 7, Issue 9: Radiology Issue - Part 1  
Volume 7, Issue 8: Environmental Medicine  
Volume 7, Issue 7: Neurology - Part 1  
Volume 7, Issue 6: Cardiology - Part 1  
Volume 7, Issue 5: Vascular Disease - Part 1  
Volume 7, Issue 4: ENT - Part 2  
Volume 7, Issue 3: Ophthalmology - Part 2  
Volume 7, Issue 2: Accident & Emergency  
Volume 7, Issue 1: ENT

### 2012 Past Issues

Volume 6, Issue 10: Ophthalmology  
Volume 6, Issue 9: Oncology  
Volume 6, Issue 8: Anaesthesia Part 2  
Volume 6, Issue 7: General Surgery Part 2  
Volume 6, Issue 6: Psychiatry Part 2  
Volume 6, Issue 5: Anaesthesia  
Volume 6, Issue 4: General Surgery  
Volume 6, Issue 3: Orthopaedics, Oral & Maxillofacial  
Volume 6, Issue 2: Rheumatology  
Volume 6, Issue 1: Geriatrics

### How We Can Help You Succeed?

To find out how 123Doc can help you dramatically increase your medical knowledge, register your interest on our website.

#### 123Doc Education

72 Harley Street  
London  
W1G 7HG

Tel: +44 (0)203 0313 866  
Web: [www.123library.org](http://www.123library.org)  
Email: [sales@123library.org](mailto:sales@123library.org)

#### ISSN

1753-6995

Designed by 123Library Limited  
Please visit [www.123library.org](http://www.123library.org)